

M. Uzan
M. Hancı
A. Ç. Sarıoğlu
M. Y. Kaynar
H. Bozkuş

Bilateral traumatic abducens nerve paralysis with cervical spine flexion injury

Received: 12 October 1995
Revised: 20 January 1996
Accepted: 8 February 1996

M. Uzan · M. Hancı · A. Ç. Sarıoğlu
M. Y. Kaynar · H. Bozkuş
Department of Neurosurgery,
Istanbul University
Cerrahpaşa Medical Faculty,
Istanbul, Turkey

M. Hancı (✉)
PO Box 792, 8220 Şişli, Istanbul, Turkey
Fax +90-212-6320026

Abstract Bilateral traumatic abducens nerve palsy is a rare condition. We report a case associated with cervical spine flexion injury. This may be the first such case report, as no similar case was found in our review of the literature. The

mechanisms of injury in this case are relevant to theories that explain hyperextension injuries.

Key words Bilateral abducens nerve palsy · Cervical spine trauma

Introduction

Ocular motor nerve palsies are common sequelae of head injuries, usually resulting from skull basilar fractures [5, 6, 9]. Rowbotham stated that the abducens nerve is frequently damaged in injuries along the petrous ridge, and he added that this is the only ocular motor nerve to be affected bilaterally [11]. It was also mentioned that nerve rootlets may be avulsed where they emerge from the surface of the brainstem [6] or may be involved at the basis pontis [9]. In 1971, Schneider and Johnson [14] reported two cases of bilateral traumatic abducens palsy associated with cervical spine fracture. Fruin and Pirote reported a case of traumatic atlantooccipital dislocation with bilateral sixth nerve palsy associated with spinal cord and lower cranial nerve injuries [3]. All previous reports stated that bilateral abducens nerve palsies can be seen as a result of extension injuries. Presented here, however, is a case of cervical dislocation with abducens nerve palsy caused by flexion injury.

Case report

A 42-year-old man was admitted to hospital suffering from multiple injuries sustained in a motor vehicle accident. On admission he was found to have multiple facial lacerations, due to explosion of the windshield, and a subcutaneous hematoma at the left supraclavicular region. He was confused and complained of severe neck pain. He had bilateral sixth nerve palsies, left Horner syndrome, and proximal weakness of the left upper extremity. Skull radiographs and computer tomography of the brain were unremarkable. Radiographs of the cervical spine showed C5-6 subluxation with opening of facet joints, increased interspinous distance, and slight kyphotic deformity (Fig. 1). The chest radiograph demonstrated fractures of the left fourth rib. The dislocation was reduced by skeletal tong traction, gradually increased up to 6 kg, using Gardener-Wells apparatus. The reduction was monitored by serial lateral cervical radiography. Two days after admission, a posterior fusion of C5-6 was performed, using Bohlmann's triple wire technique. During the early postoperative period the patient suffered respiratory difficulty caused by pneumonia superimposed on chronic obstructive lung disease. A tracheostomy was performed and the patient was mechanically ventilated for 7 days. He was discharged 1 month later with a firm-fitting collar. At this time, he was alert and movement of the left shoulder had returned to normal. The Horner syndrome was markedly improved with only bilateral abducens palsy persisting (Fig. 2). One year after surgery, bony fusion had been achieved and the sixth nerve palsies had completely healed.

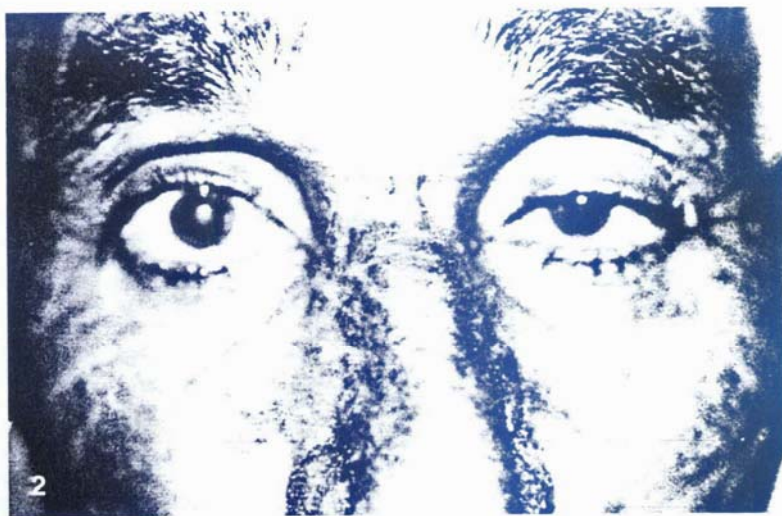
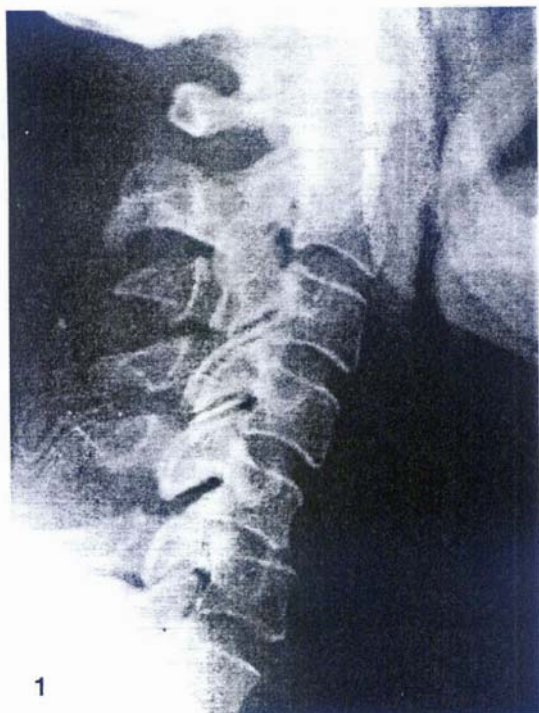
Fig. 1 Lateral radiograph of the cervical spine on the day of injury, showing C5-6 dislocation and increased interspinous distance

Fig. 2 Photograph of the patient taken 4 weeks after the accident, demonstrating bilateral lateral rectus palsies, more prominent on his left side

Discussion

Rucker [12] and Rush and Young [13] found 112 isolated traumatic sixth nerve palsies among 2,000 cases of varying etiologies (e.g., tumor, trauma, or vascular conditions). Of these, only 11 cases were bilateral, most of them involving the sixth cranial nerve. However, Rucker did not analyze cases of bilateral involvement. Only 8 of the 11 patients with bilateral traumatic abducens palsy were without skull and cervical spine fractures [1, 4, 7, 10, 14, 16]. The mechanism of injury in the acute form of bilateral traumatic abducens nerve palsy without skull fracture remains controversial [1].

Severe midfrontal impact with marked cervical hyperextension sometimes causes spine fractures. Schneider and Johnson suggested that the upward and posterior displacement of the brain produced by midfrontal impact causes avulsion of the abducens nerve against the rigid Grüber's ligament [14].

However, Takagi et al. stated that it is impossible to damage the abducens nerve at Grüber's ligament by upward movement of the brain, because the abducens nerve is fixed downward below this ligament by the dura mater and the apex of petrous pyramid [16]. They suggested that both abducens nerves are stretched and contused against the ridge of the petrous pyramid at the time of impact by a linear force.

All previous reports have pointed out that extension injuries are a cause of abducens nerve palsy [1, 4, 7, 10, 14-16]. In this case, however, the major trauma vector

was distractive flexion [2]. If a force F_1 is applied to the head at an angle, according to an XY coordinates system, it will have two resultants: $(F_1) X$ and $(F_1) Y$. $(F_1) X$ is the horizontal resultant and $(F_1) Y$ is the vertical one. The vertical component in both flexion and extension injuries is similar. Our vectorial analysis of the forces of injury demonstrated that hyperflexion can produce the same upward brainstem displacements as those seen in extension

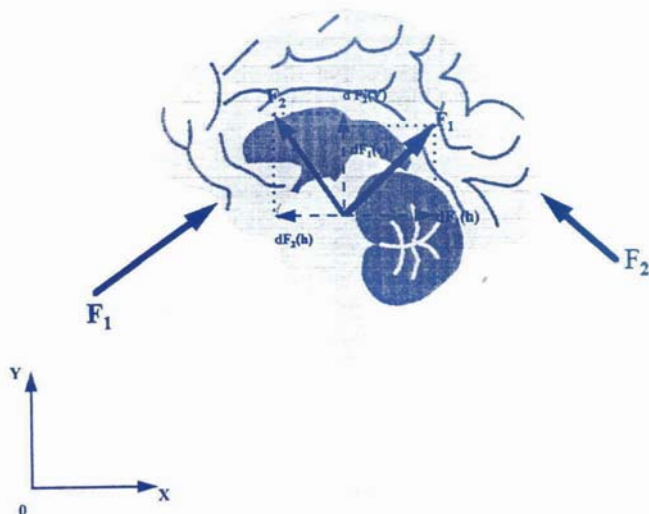


Fig. 3 Vectorial analysis of the forces involved in flexion injuries. F_n Force. dF_n displacement resulting from F_n , $(dF_n)h$ horizontal resultant of dF_n , $(dF_n)v$ vertical resultant of dF_n

injuries (Fig. 3). Consequently, this mechanism of injury can produce the same type of abducens nerve lesion as has been documented in extension injuries.

Acknowledgement The assistance of Kadri Celasun and Linda Mikilauskas in the preparation of this paper is gratefully acknowledged.

References

1. Arias MJ (1985) Bilateral traumatic abducens nerve palsy without skull fracture and with cervical spine fracture: case report and review of the literature. *Neurosurgery* 16:232-234
2. Bauer RD, Errico TJ (1991) Cervical spine injuries. In: Errico TJ, Waugh T, Bauer RD (eds) *Spinal trauma*. Lippincott, Philadelphia, pp 71-122
3. Fruin AH, Pirote TP (1977) Traumatic atlantooccipital dislocation. *J Neurosurgery* 46:663-666
4. Goubran GF (1978) Traumatic bilateral abducens nerve palsies. *Br J Oral Maxillofac Surg* 15:268-275
5. Grange JD, Bonamour G (1974) Sequelles oculaires tardives des traumatismes craniens fermes de l'adulte. *Rev Pract* 24:2845-2854
6. Heinze J (1969) Cranial nerve avulsion and other neural injuries in road traffic accidents. *Med J Aust* 56:1246-1269
7. Helliwel M, Robertson JC, Todd GB, Lobb M (1984) Bilateral vocal cord paralysis due to wiplash injury. *Br Med J* 288:1876-1877
8. Keane JR (1992) Locked-in syndrome after head and neck trauma. *Neurology* 36:80-82
9. Keane JR (1992) Posttraumatic cranial neuropathies. *Neurol Clin* 10:849-867
10. Neetens A, Selloose P (1977) Oculomotor anomalies in sellar and parasellar pathology. *Ophthalmologica* 175:80-104
11. Rowbotham GF (1964) *Acute injuries of the head: their diagnosis, treatment, complications, and sequels*. Williams and Wilkins, Baltimore
12. Rucker CW (1958) Paralysis of the third, fourth, and sixth cranial nerves. *Am J Ophthalmol* 46:787-794
13. Rush JA, Young BR (1981) Paralysis of cranial nerves III, IV, and VI. *Arch Ophthalmol* 99:767-779
14. Schneider RC, Johnson FD (1971) Bilateral traumatic abducens palsy: a mechanism of injury suggested by the study of associated cervical spine fractures. *J Neurosurg* 34:33-37
15. Shifrin LZ (1991) Bilateral abducens nerve palsy after cervical spine extension injury. A case report. *Spine* 16:374-375
16. Takagi H, Miyasaka Y, Kuramae T, Ohwada T, Tsunoda M (1976) Bilateral traumatic abducens nerve palsy without skull fractures or intracranial hematoma: a report of 3 cases and consideration of the mechanism of injury. *Neurol Surg (Tokyo)* 4:963-969