

INTRAORBITAL PATHOLOGIES

Ziya AKAR M.D., Emin ÖZYURT M.D., Bulent CANBAZ M.D., Cengiz KUDAY M.D., Ertuğrul SAYIN M.D., Murat HANCI M.D.

Istanbul University, Cerrahpaşa Medical Faculty Department of Neurosurgery İstanbul / TÜRKİYE

Turkish Neurosurgery 1 : 154-158, 1990

SUMMARY :

Forty-eight patients with intraorbital pathologies treated surgically and the literature are reviewed.

Fifty per cent of the patients (28 male and 20 female) were between one and 20 years old. 26 cases had right and 22 left exophthalmus, 23 cases had 2nd, 3rd, 5th, and 6th nerve palsies. In 15 cases chemosis and in 13 cases pain (around the orbit) were observed. Pathological findings on plain x-ray were found in only 26 cases. In 33 (68.75%) cases tumoural and in 15 (31.25%) cases nontumoural pathology was found. Orbital unroofing, lateral orbitotomy, percutaneous needle puncture and embolisation were the treatments used.

KEY WORDS :

Orbit, orbital diseases, orbital tumours.

INTRODUCTION :

The orbita is a bony compartment which contains the globe, extraocular muscles, nerves, vessels, the lacrimal glands and adipose tissue. Conically shaped, with the apex directed medially, it has a volume of approximately 30cc, 6.5cc of which is the globe (1). Because of the organ it contains and its position, the orbita has an important function and is an aesthetically important part of the body. The orbita and its contents, the surrounding tissues or a metastatic process can be the cause of pathology. In addition infections and trauma can cause orbital pathologies. Because of its structure and the various sources of pathologies involved, the authors discuss the best treatment and operative approach.

Since there are many kinds of treatment, such as systemic and/or focal medical treatment, chemotherapy, or radiotherapy orbital pathology usually needs multidisciplinary evaluation.

Orbital deformation or loss of vision are the most common symptoms caused by a mass lesion and the diagnosis must be made after detailed physical and radiological examination. If surgery is indicated, a surgical plan must be made carefully, considering possible secondary defects.

Our experience of orbital pathologies, evaluated and surgically treated in the University of Istanbul Cerrahpaşa Medical Faculty, has been reviewed and compared with the literature.

MATERIALS AND METHODS :

Forty-eight patients with identified intraorbital pathology hospitalized between 1982 and 1989 were studied retrospectively. All the cases were treated sur-

gically in the University of Istanbul Cerrahpaşa Medical Faculty Department of Neurosurgery. Clinical features (age, neurological and neuroophthalmological findings, site of the pathology, etc.), radiological findings, histopathology, surgical technique and the survival were discussed and results were compared with the literature.

RESULTS :

Twenty-eight cases were male (58.3%) and 20 were female (41.7%) (Fig. 1). Fifty per cent of the patients were between one and 20 years of age (Fig. 2). The childhood group included 17 (25.4%) cases. The youngest patient was two and the oldest 72 years of age. The mean age was 30.6.

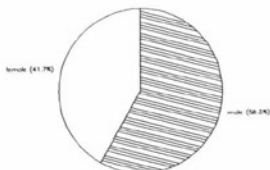


Fig. 1 :

Varying degrees of proptosis were observed in all patients. 26 had proptosis in the right eye and 22 in the left. The direction of the proptosis depended on

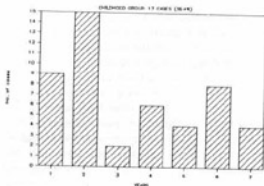


Fig. 2:

the site of the pathology. Axial (18) and down-looking exophthalmus were more frequent. In addition to exophthalmus, other complaints, pain (around the orbit) and visual field defects. 2nd, 3rd, 5th and 6th nerve palsies (single or combined) were observed in 23 (48%) patients. Optic nerve involvement was more prominent in 18 (37.5%) cases. The symptoms and signs of the patients are shown in Fig 3 : and Table : 1.

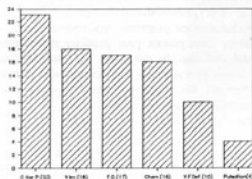


Fig.3 : Clinical findings.

TABLE : 1 CLINICAL FINDINGS

CRANIAL NERVE PALYS	23
2	14
6	3
3-6	1
5-6	1
2-3-6	4
CHEMOSIS	15
PULSATION	4
VISUAL IMPAIRMENT	18
Blindness	1
0-1m	5
1m-1/10	5
1/10-10/10	5
VISUAL FIELD DEFECT	10
Centric	2
Quadrantic	2
Scotom	5
FUNDOSCOPIC FINDINGS	17
Atrophy	13
Edema	4

In 27 patients (56%) plain skull plus orbita x-rays revealed pathological findings (Tab : 2). Angiography was performed in 31 patients but pathological signs were found only in 5 (10%) (3 blushing, 2 vascular anomalies). CT was performed in all cases and pathology was seen in all.

TABLE : 2 PLAIN X-ray FINDINGS

FINDING	No of CASES	PATHOLOGY
High density	8	Meningioma, Osteoma, Mucosel, Haemangioma, Fibrous Dysplasia.
Lytic Lesion	4	Epidermoid, Meningioma, Infection.
Hyperostosis	4	Osteoma, Fibrous Dysplasia.
Fracture	2	Blow out Fracture, Carotico-cavernous Fistula.
Destruction	8	Meningioma, Hydatid Cyst, Adenoma, Abscess, Encephalocoele, Fibrous Dysplasia, Rhabdomyosarcoma, Adenocarcinoma Metastasis.

Pathology was intracanal in 20 (40%) cases and extra-canal in 28 (60%). Pathology was observed superiorly in 20 cases laterally in 8, medially in 4, inferiorly in 2 and apex in 14 according to the surgical anatomy (Fig. : 4).

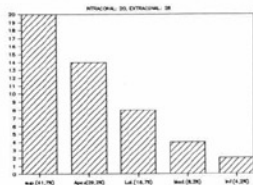


Fig. 4 : Localization of pathologies.

In 33 cases (68.75%) tumoural and in 15 (31.25%) nontumoural pathology was found. 16 neural and 8 osseous pathologies formed the tumoural group. The 15 nontumoural pathologies included 5 infectious, 4 trauma and 6 different pathologies (Fig.5). In the childhood group there were 12 tumoral and five nontumoural cases (Table : 3,4).

The transcranial approach was the most used for the treatment of orbital pathologies (44 cases). Lateral orbitotomy in one case and embolisation techniques in 2 cases were preferred in our series. The

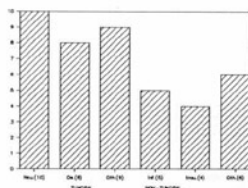


Fig. 5: Orbital pathologies.

TABLE 3 TUMORAL ORBITAL PATHOLOGIES (33 cases 68.75%)

NEURAL 16	OSSEOUS 8	OTHER 9	
Optic glioma	4 Fibrous dysplasia	5 Metastasis	1
Meningioma	5 Osteoma	3 Adenoma	1
Neurinoma	1	Haemangioma	3
Neurofibroma	3	Epidemoid	2
		Rabdomyosarcoma	2

TABLE 4 NON-TUMORAL ORBITAL PATHOLOGIES

INFECTION 5	TRAUMA 4	OTHER 6	
Hydatid Cyst	1 Blow outfracture	2 Mucocoele	2
Abscess	2 Caroticoavernous	Pseudotumour	3
Infection	1 Fistula	2 Encephalocele	1

pathologies were removed totally in 28 cases, sub-totally in 12, and only optic canal decompression was performed in two cases. In one patient with widespread rabdomyosarcom orbital exenteration was performed at the same operation.

After surgical treatment 38 cases (79%) completely recovered and six remained the same. One optic sheath meningioma, one haemangioma and two osteomas localized around the optic canal became worse.

Decrease of visual acuity, chemosis, infection, paralysis of the extraocular muscles were seen in 10 patients in the early postoperative period. These findings disappeared within a few days with drug therapy.

DISCUSSION :

The characteristics of series of intraorbital pathologies vary due to racial characteristics, socioeconomic levels and the specialities of the authors. Definitions of pathological types differ in dif-

ferent series, but there are common points in typing the pathological groups (tumoural or nontumoural). Generally tumours are the most common type of orbital pathology, neurogenic tumours, haemangiomas, metastatic tumours, tumours of the lacrimal gland and osseous tumors being the most common (8,10,12,14,16,22). On the other hand some authors (4,13,18) report inflammatory pathologies as the most common, and in this group pseudotumours and endocrine exophthalmia have a high percentage. We confirmed in our series that 68.75% were tumoural and 31.25% nontumoural: 48% of the tumoural pathologies were of neural origin, and the others were mostly osseous. In some series lymphomas were the most common tumoural groups after haemangioma and optic glioma. In our series however we found no lymphomas (10), and about 17 per cent were nontumoural.

Pathologies that originate in or invade the orbit produce symptoms and signs by compression, infiltration and/or infarction of the orbital structures (7,10,15). The most common clinical findings caused by orbital pathologies are: proptosis, optic neuropathy, ocular motor nerve paresis, pain, pupillary abnormalities and chemosis. In our series the most common features were proptosis, cranial nerve palsy, pain and chemosis. We found no isolated pupillary abnormalities, probably because tumours that produce pupillary sympathetic or parasympathetic nerve palsy are usually so extensive that they produce oculomotor nerve palsy with pupillary involvement as well. Thus, if there is damage to either the sympathetic or parasympathetic fibres it is usually masked by the oculomotor nerve palsy.

Correct diagnosis of orbital pathology has increased since the use of high resolution computed tomography (6,10,19,20). CT revealed pathology in all the cases in our series.

Pathological findings on direct x-rays were found in only 26 cases (56%). These findings were definite especially in the osseous tumours and meningiomas and our percentage was higher than that in Llyod's series of 1070 cases, when a definite diagnosis was made in 21 percent (6.10.11).

Angiography which needs techniques such as selective catheterization, magnification, or subtraction is not often used in the evaluation of primary orbital pathology. Its principal role is in detecting small vascular tumours such as meningioma and haemangioma (6,8,10). Showing vascular displacement is very difficult since it is generally small, and is why only 10 percent of pathological findings were

found in our 31 patients in which angiography was performed (2 meningioma, 1 hemangioma, 2 carotico-cavernous fistulas). The direction of orbital veins is more stable than arterial directions, so orbital venography is more significant for showing intraorbital pathology than arteriography (6.8.10).

The orbita can be divided into 4 parts (1): 1) Superiosteal space, 2) Extraconal space, 3) Intraconal space, 4) Tenon space. The orbita has 5 sides, all the orbital walls may be used to reach the pathology. Generally there are four different types of approach (1,2): 1) Superior surgical approach, through the superior wall used during transcranial or transfrontal orbitotomy, 2) Lateral surgical approaches, external lateral or temporal orbitotomy is access through the temporal fossa (Krönlein technique or its variations) (Fig 6), 3) The anterior surgical approach can be performed through the eyelid or the conjunctiva (transethmoidal orbitotomy, transmaxillary orbitotomy) (Fig 7), 4) Percutaneous needle puncture. The route of access to the orbit is chosen according to the pathological condition (for example size, vascularisation, probable character of pathology) and surgeon's specialisation (experience, working team and knowledge about of the orbital pathology) (1,2,3,7,8,12,13,21). It is possible to make a true diagnosis during the preoperative period with delicate neurological examination and using new diagnostic techniques for optic nerve or sheath pathologies (1,8,10,18,19,20). This evaluation is important for choosing the surgical approach. The transcranial approach was used in 44 cases, lateral orbitotomy in one, percutaneous needle puncture in one case and embolisation in two cases (carotico-cavernous fistula).

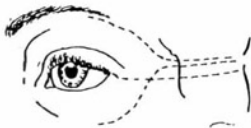

Fig 6: Variation of lateral orbitotomy.

Optic gliomas become manifest during the first decades of life and incidence increases with neurofibromatosis. They are usually low grade tumours (grade 1-2), with 0.6-1.2 percent incidence among cases of unilateral proptosis (3,8,10,15,17). Optic glioma may be in the prechiasmatic region in 23-36 percent

in the chiasma, tractus region (17). Adult optic gliomas are high grade astrocytomas, and progress more rapidly than childhood astrocytomas (6,8).

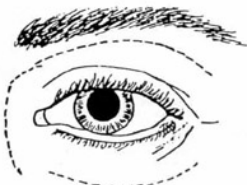


Fig 7: Variation of anterior orbitotomy.

Therapeutic methods depend on the chiasmatic infiltration. The authors Llyod, McKeran, Hoyd, Donol, Robert who have large series, recommend extirpation of the glioma by cutting the optic nerve in front of the chiasma and just behind the globe if the tumour is in the prechiasmatic region and does not infiltrate the chiasma in patients whose vision is impaired and who have progressive proptosis (3,4,9,11,12,13,17). They recommend only biops and RT if chiasmatic infiltration is present. Our general practice is to evaluate the vision and CT estimation of the tumor size if the glioma is intraorbital and confined to one nerve. If vision is seriously impaired and proptosis is progressive we use radical surgical techniques to eliminate any change of chiasmatic spread. Four patients on whom we performed total extirpation, had 0-1m vision before the operation and to date none has had tumoural recurrence.

The efficiency of RT is suspect in the literature for optic nerve or sheath tumours, but some authors say it is 50 percent useful for patients with tumours sited posteriorly (chiasma, tractus) and those in whom partial tumoural resection has been performed (17).

There is some controversy about repair of the orbital roof after unroofing (1,2,5,13). When exposure of the orbital cavity has been extensive, or when a subsequent operation such as orbital exenteration is planned, repair of the orbital roof is recommended. The repair can be done either with a sheet of plastic polymer or with a bone graft. We could not repair the orbital roof after orbital unroofing in our cases but did not observe any problems during the early and late stages of the operation.

We observed some complications, such as chemosis, ptosis, extraocular motor nerve palsies, impairment

of vision, in 10 patients during the early postoperative period which improved within days. The signs regressed with corticosteroid therapy and were probably temporary paralysis of the levator palpebra and superior rectus muscles due to surgical manipulation during the transcranial approach reported in the literature (2,4).

Correspondance : Ziya AKAR M.D.
 I.Ü. Cerrahpaşa Tıp Fakültesi
 Nörolojisi Anabilim Dalı
 Aksaray / İSTANBUL

REFERENCES :

- Alper MG, Aitken PA. Anterior and lateral microsurgical Approaches to orbital pathology, in Schmidek HH, Sweet WH (EDS). Operative Neurosurgical Techniques. New York: Grune and Stratton 1982, vol 1, pp.227-245
- Brihaye J. Neurosurgical Approaches to Orbital Tumors, in Krayenbuhl H (ED). Advances and Technical Standards in Neurosurgery New York: Springer-Verlag 1976, Vol 3, pp.103-123
- Donald CO, Martin FS. The dilemma of childhood optic gliomas. J Neurosurg 48:34-41, 1978
- Dorlin ML. Neurosurgical involvement in Tumors of the orbit, in Little JR (ED). Clinical Neurosurgery. Baltimore: Williams and Wilkins 1984, pp.514-527
- Eugino P, Giuliano G, and Giulio G. Orbital surgery. Repair of frontal fossa by "En bloc" removal and self-replacement of the orbital roof. Surg Neurol 30:159-161, 1988
- Gleen F. Radiological evaluation of Orbital Tumors, in Little JR (ED). Clin Neurosurg. Baltimore: Williams and Wilkins 1964, pp. 474-514
- Housepain EM, Trokel SL, Jakobiec FO. Tumors of the orbit, in Youmans JR (ED). Neurological Surgery. Philadelphia: W. b. Saunders Company 1982, Vol 5, pp. 3024-3065
- Housepain EM. Intraorbital tumors, in Schmidek HH, Sweet WH (EDS). Operative Neurosurgical Techniques. New York: Grune and Stratton 1982, Vol 1, pp.227-245
- Hoyt WF, Baghassarian SA. Optic glioma of childhood. Natural history and rationale for conservative management. Br J Ophthalmol 53:793-798, 1969
- Lachaw RE, Rothfus WE. Radiology of the orbit and its contents, in Wilkins RH, Bengachary SS (EDS). Neurosurgery. New York: Mc Graw-Hill Book Company 1985, Vol 1, pp.952-964
- Lloyd LA. Gliomas of the optic nerve and chiasm in childhood. Trans Am Ophthalmol 71:488-535, 1973
- Maroon JC, Kennerdell JS, Abilo A. The Diagnosis and Treatment of Orbital Tumors, in Little JR (ED). Clinical Neurosurgery Baltimore: Williams and Wilkins 1985, pp.485-498
- Maroon JC, Kennerdell JS. Surgical approaches to orbit. J Neurosurg 60:1226-1235, 1984
- Masaaki O, Keisuke T, Shoji A, et al. Multiple cavernous Hemangiomas of orbit. Surg Neurol 29:32-34, 1988
- Miller NR. Neuro-ophthalmology of Orbital Tumors, in Little JR (ED). Clinical Neurosurgery. Baltimore: Williams and Wilkins 1984.
- Peter DF, Devron HC. Bilateral orbital cavernous haemangiomas. Br J Ophthalmol 72:871-873, 1988
- Robert T, Edward W Jr, Brain RY, et al. The neurosurgical management of optic glioma. J Neurosurg 57:452-458, 1982
- Rothfus WEI, Curtiss HD. Extraocular muscle enlargement. ACT review. Radiology 151:677-681, 1984
- Rothfus WE, Curtiss HD, Slomowitz TL. Optic nerve/sheath enlargement. Radiology 150:409-415, 1984
- Seungho HL, Krishna CVG. Cranial computed tomography and MRI, in Krayenbuhl H (ED). New York: Mc Graw-Hill book Company, second edition 1987
- Solomon BA. Sphenoorbital Approach to the optic nerve, in Schmidek HH, Sweet WH (ED). Operative Neurosurgical Techniques. New York: Grune and Stratton 1982, Vol 1, pp.279-291
- Tunchay E, Övül İ. Tek taraflı eğeralsini ve orbita tümörleri. Cerrahpaşa Tıp Fak. Derg. 14:253-258, 1983