



Late onset Pott's paraplegia

N Bilsel*¹, Ö Aydingöz¹, M Hancı² and F Erdoğan¹

¹Department of Orthopaedics and Traumatology, Cerrahpaşa Faculty of Medicine, University of İstanbul, Turkey;

²Department of Neurosurgery, Cerrahpaşa Faculty of Medicine, University of İstanbul, Turkey

Background: Pott's disease may cause late neurological involvement due to development of sharp kyphosis. Anterior decompression and fusion is the treatment of choice for this disorder.

Objective: To determine the mid-term clinical results of patients with late onset Pott's paraplegia, who underwent anterior decompression and grafting after neurological deterioration.

Setting: A university hospital in İstanbul, Turkey.

Methods: Eight patients who developed late onset paraplegia with a mean period of 24.6 years (range, 9–46 years) after the active disease were treated with anterior decompression and grafting. The mean age at surgery was 36.1 years (range, 18–63 years) and the mean duration of neurological deterioration before surgery was 7.4 weeks (range, 2–13 weeks). The mean kyphosis angle of the patients was 105.63° (range, 80°–135°). No attempt to correct the curve was made in any operation. All but two patients' neurological status were evaluated according to the International Standards for Neurological and Functional Classification of Spinal Cord Injury determined by ASIA-IMSOP on admission.

Results: Neurological status of all patients showed progression either in Frankel scale or in motor scores in the early postoperative period. One patient needed to be reoperated on because of a deterioration of neurological status 26 months after surgery. The mean length of time since the operations is 75.9 months (range, 48–173 months) and all the patients are carrying out their lives independently with a mean motor score of 97.5 and full pin-prick and light touch scores.

Conclusions: Anterior decompression and grafting is an effective procedure for the treatment of late onset paraplegia in Pott's disease.

Spinal Cord (2000) **38**, 669–674

Keywords: tuberculosis; Pott's paraplegia

Introduction

Tuberculosis is still an important health problem in developing and also developed countries with significant morbidity and mortality rates, despite the decreasing incidence. On the other hand, the importance of the disease is gradually increasing from a controlled level in developed countries, with significant numbers of new cases, parallel to the increase in the number of patients with AIDS. Magid reported that tuberculosis should be considered in any patient with AIDS because of its disproportionately high prevalence in some series.¹ Approximately 30 million patients are treated because of tuberculosis in the world and 8 million new cases are added every year.²

Tuberculosis involves mostly (nearly 50%) the spinal column in the musculoskeletal system.² Tuberculosis of the spine has two major complications: neurological deficit and the kyphosis. Neurological

involvement may occur during the course of or years after the active disease.^{3–5} Kyphotic deformity of 0–10° in 85%, 11–30° in 12%, and more than 30° in 3% of the patients with Pott's disease is the outcome.² Sharp kyphosis deformity, that is mostly developed in children, is the cause of serious cardiovascular, respiratory and psychological problems, and also is the leading factor for the development of late neurological problems. Another problem in these patients is the impingement of the ribs on the ilium in addition to the cosmetic problems.

It has been reported that late onset Pott's paraplegia has a relatively poor prognosis compared with the early onset paraplegia.⁶ Timing of the surgical intervention after the beginning of symptoms of late neurologic involvement is still controversial.^{2,5}

In this study we aim to give the results of the treatment of eight patients who were admitted with late onset Pott's paraplegia due to sharp kyphosis deformity and discuss some details about the management of these cases.

*Correspondence: N Bilsel, University of İstanbul, Cerrahpaşa Faculty of Medicine, Department of Orthopaedics & Traumatology, 34303, İstanbul, Turkey

Materials and methods

Eight patients, consisting of four men and four women with Pott's kyphosis and late neurological involvement, were treated in our institution by anterior decompression and grafting between 1985 and 1995 (Table 1). The mean age of these patients at the operation was 36.1 years (range, 18–63 years) and the mean follow-up was 75.9 months (range, 48–173 months). History of tuberculosis ranged from 9 to 46 years (mean: 24.6 years). The beginning of the disease was the first decade in all of the patients except the fourth case. All of the patients had a history of previous surgery and costotransversectomy incision scars were seen in physical examinations and all of them had received antituberculous therapy for unknown periods. In thoracic region, abscess drainage via costotransversectomy was the treatment of choice in Turkey, before the anterior procedures became popular. The mean kyphosis angle of the patients was 105.63° (range, 80°–135°). All patients except the second and seventh had problems related to the impingement of the ribs on the ileum.

All patients underwent anterior decompression and anterior fusion by anterolateral approach. All operations were performed by the senior of us (N Bilsel). In all cases the aorta was observed to lie within the kyphotic deformity due to the pull of the intervertebral arteries. The aorta was freed with meticulous dissection and taken away from the operative field to prevent iatrogenic damage during the procedure.

Vertebral bodies were found to lose their original shapes due to the infection and formed a U-shaped coalesced bony structure with the progression of irregular spontaneous fusion. Various degrees of granulation tissue formation and sequester were observed in all patients. Anterior decompression was carried out and anterior transposition of the spinal cord was achieved. Anterior fusion was done by using rib grafts in order to prevent the increase of the kyphotic deformity. No attempt to correct the deformities had been made. External support (either with a cast or brace) was used postoperatively for a period of 6–8 months in every patient.

Although no indication of active disease in any patient existed preoperatively, infectious fluid was observed within small cavities during the operation of each patient (Figure 1). All patients received antituberculosis drug therapy postoperatively for a period of 9–12 months although Koch bacillus could not be grown in the specimens taken. Isoniazid, rifampicin, pyrazinamid and streptomycin were used in all patients.

Neurological status of all patients on admission and during follow-up were evaluated according to the Frankel scale.⁷ All but two patients' neurological status were evaluated according to the International Standards for Neurological and Functional Classification of Spinal Cord Injury determined by ASIA-IMSOP on admission.⁸ These two patients could not be evaluated with that system, because that scoring was not available at the date of their admission. Preoperative sensory and motor scores according to the *International Standards for Neurological and Functional Classification of Spinal Cord Injury* of six out of eight patients were also available (Table 2). The mean motor score of them was 69 with normal pinprick and light touch scores.

Results

No early post-operative complications were encountered and the neurological status of the patients recovered within the first week postoperatively. Preoperative and postoperative neurological statuses of the patients were given in Table 2. In one of the patients (third patient) a deterioration of the neurological status was observed (his motor score decreased to 84 from 90) 26 months after the anterior decompression. The gibbus angle was also worsened from 125° to 135° due to poor anterior grafting and he was hospitalized again. A second anterior decompression was performed by using the same incision and approach. As a result of the exploration it was decided that the size of the graft used in the first operation was insufficient and caused the increase in the gibbus angle. Although no macroscopic lesion was observed in the neural structures in the apex of the

Table 1 Preoperative data

Patient No.	Sex	Age	History of tbc (year)	Gibbus level	Neurologic at level	Gibbus angle	Duration of neurological deterioration (weeks)	Operation date
1	F	47	38	T10–L2	T11	135	13	10.6.85
2	F	19	13	T12–L1	T12	85	4	12.5.91
3	M	18	9	T3–L1	T8	125	6	11.5.93 1.8.95
4	F	63	30	T9–L2	T8	105	7	10.1.95
5	M	18	10	T10–T12	T11	120	9	6.6.95
6	M	35	29	T8–T9	T8	80	13	2.10.95
7	M	57	46	T10–L1	T11	95	5	13.10.95
8	F	32	27	T3–L1	T8	100	2	24.11.95

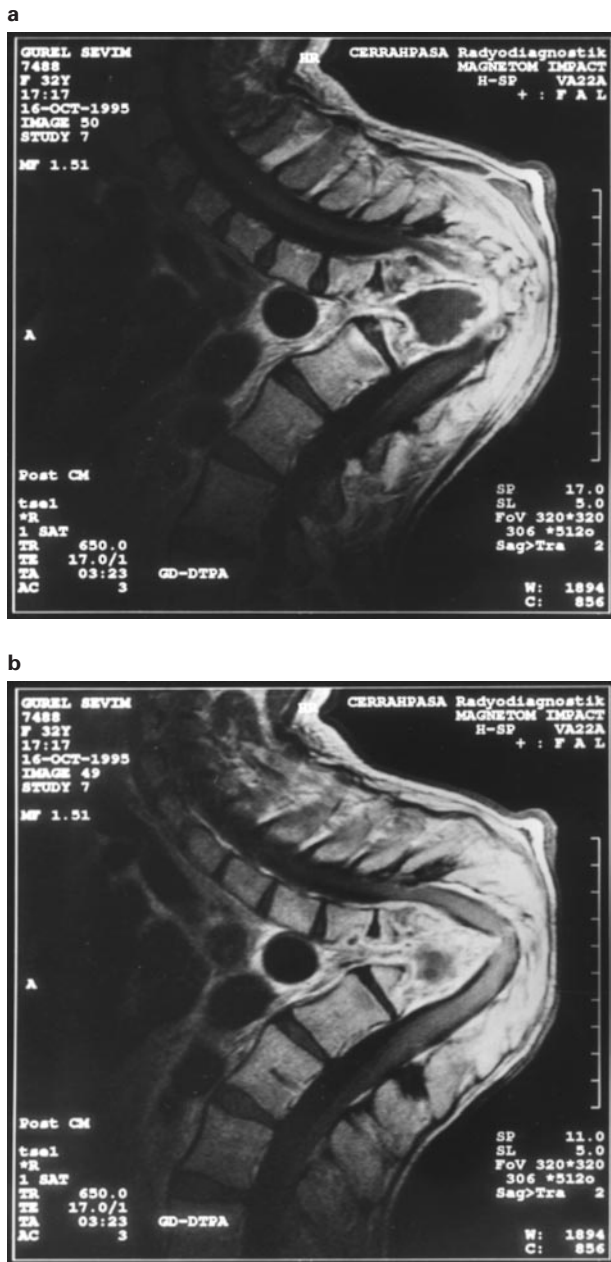


Figure 1 (a) T1-weighted sagittal MR image of Case 8 showing abscess formation, (b) Medullary compression is seen at the apical region of the curvature in the midline sagittal image

deformity, the motor score of the patient became 60 postoperatively. His motor score advanced back to 90 after an intensive rehabilitation program within 2 months and he was maintaining this situation at the latest follow-up (77 months after the first operation).

The mean follow-up time of the patients was 75.9 months (range 48–173 months). Their mean motor score at the latest follow-up was 97.5 (range, 90–100) and all of them had full sensory scores (Table 3). The only problem related to the graft had occurred in case

three as mentioned above. No problem related to the graft size or placement was encountered in other patients (Figure 2).

Discussion

There are many reasons for the neurological deficit seen in Pott's disease and various classifications of Pott's paraplegia have been made. The first classification was made by Sorrel and Dejerine in 1924.³ Paraplegia was divided into two groups as early onset and late onset in this classification. Sedon and Butler modified this classification and divided the paraplegia into three groups. Sedon also described late onset paraplegia (as Type III) in his classification and pointed out that the prognosis is doubtful in these cases.

Hodgson *et al* described two basic groups in preoperative evaluation of the lesion.⁴ Group A: paraplegia with active disease, which included two subtypes: (1) external pressure on the cord; (2) penetration of the dura by infection; Group B: paraplegia of healed disease, which included two subtypes: (1) transection of the cord by a bony ridge; (2) constriction of the cord by granulation and fibrous tissue.

The cause of the late onset Pott's paraplegia is the sharp kyphosis deformity, which is an outcome in some of the patients. The deformity may show progression and with the increase in the gibbus angle, the posterior spinal muscles act as contributors to the deforming force, with a mechanical disadvantage especially after 45° of deformity. Neurological involvement is a possibility in the course of the disease. In many patients neurological symptoms of a late onset paraplegia occurs more than 15 years after the initial disease. That can occur due to the compression of the spinal cord by healed bony bars, calcified caseous material, fibrosis, increasing deformity at the internal kyphus or, not commonly, reactivation of the disease.⁵ The more severe and the more proximal the deformity, the worse the prognosis of the neurologic deterioration. The distraction of the spinal cord in the kyphotic area may cause ischemia and spinal tract atrophy and gliosis can be the outcome. Both the effects of this distraction and the direct compression to the spinal cord may be the cause of the paraplegia.

Although the frequency of late onset Pott's paraplegia is lower than early onset paraplegia, kyphotic deformities secondary to Pott's disease carry a high risk of neurological problems in long term period.² This risk is more prominent especially in kyphosis developing after childhood Pott's disease.⁵ Growth continues in the posterior part of the affected segments of spinal column while it ceases in the anterior part because of the fusion and progressive sagittal deformity arises. Rayascharan *et al* developed a formula to predict the degree of spinal gibbus deformity.⁹ This may be useful in early

Table 2 Comparison of preoperative and postoperative neurological data (at 3rd month)

Patient No.	Frankel grade	Preoperative			Frankel grade	Postoperative		
		Motor score	Pin prick score	Light touch score		Motor score	Pin prick score	Light touch score
1	B	NA	NA	NA	E	NA	NA	NA
2	C	NA	NA	NA	D	NA	NA	NA
3	C	72	112	112	D	92	112	112
4	C	70	112	112	E	99	112	112
5	C	68	112	112	E	98	112	112
6	C	69	112	112	E	100	112	112
7	C	66	112	112	E	100	112	112
8	C	69	112	112	E	100	112	112

NA = not available

Table 3 Clinical outcome at latest follow-up (minimum of 48 months)

Patient No.	Follow-up period (months)	Frankel grade	Motor score	Pin prick score	Light touch score
1	173	E	100	112	112
2	101	D	92	112	112
3	77	D	90	112	112
4	58	E	100	112	112
5	52	E	98	112	112
6	49	E	100	112	112
7	49	E	100	112	112
8	48	E	100	112	112

identification of patients with a high risk of developing severe gibbus deformity and early surgical intervention, i.e., radical excision of the tuberculosis focus and bone grafting, may be carried out to prevent late complications. However, Tuli reported that it is difficult to estimate the initial loss of height of the vertebral bodies in children from radiographs.²

Hsu reviewed 22 patients with late onset Pott's paraplegia.¹⁰ Operative findings in his series revealed that eight of his 22 patients showed a complete healing while active disease was present in the remaining 14 patients. He accepted pus or caseous material, granulation tissue, sequestra larger than 5 mm, healed bony ridge and dural fibrosis as indications of active disease. We found one or more of these features of active disease in each of our patients.

All of the patients in our series had costotransversectomy scars of previous abscess drainage in the active phase of the disease. This may be a contributing factor to the late development of the kyphos deformity due to the bony resections during these procedures.

There is a consensus on the treatment method of the late onset Pott's paraplegia. All authors agree that anterior decompression and fusion is the treatment of choice. Correction of the sagittal deformity is a matter of controversy. Some authors are trying to achieve a correction in the deformity, while some others leave the deformity untouched because of the high neurological complication rates.^{5,6} We also do not attempt to correct the deformity in these cases.

The selection of appropriate graft size and placement is a critical issue during operation. Graft length is another issue as shown by Rajasekaran *et al*, in their review of 85 Pott patients treated by debridement and anterior arthrodesis.¹¹ They found a strong correlation between the quality of the results and the length of the graft, i.e. the longer the graft, the poorer the result. Although this is not a study of patients with late Pott's paraplegia, this may give us some clues about the graft use in late paraplegia cases. One of our patients (case 3) needed to be reoperated on due to the problems related with inappropriate graft size and placement. The problem in that patient was not the graft's being a long one but its inappropriate (short) size and placement. A longer graft was placed with a better orientation in the revision operation of this patient.

Tuli reported that, between 1965 and 1970 they carried out operative decompression in every case of severe kyphosis with neurological involvement, but as the results of anterior decompression procedure were not satisfactory, they changed their philosophy since 1971 in order not to rush to operate on the patients with grade 1 or 2 paralysis; instead they kept them under close observation.² However, the moment a patient was unable to walk, they performed an anterior decompression and fusion operation.

Tuli also reported that antituberculosis drugs were given before and after the operation and the neurological recovery in 33 patients, with a deformity

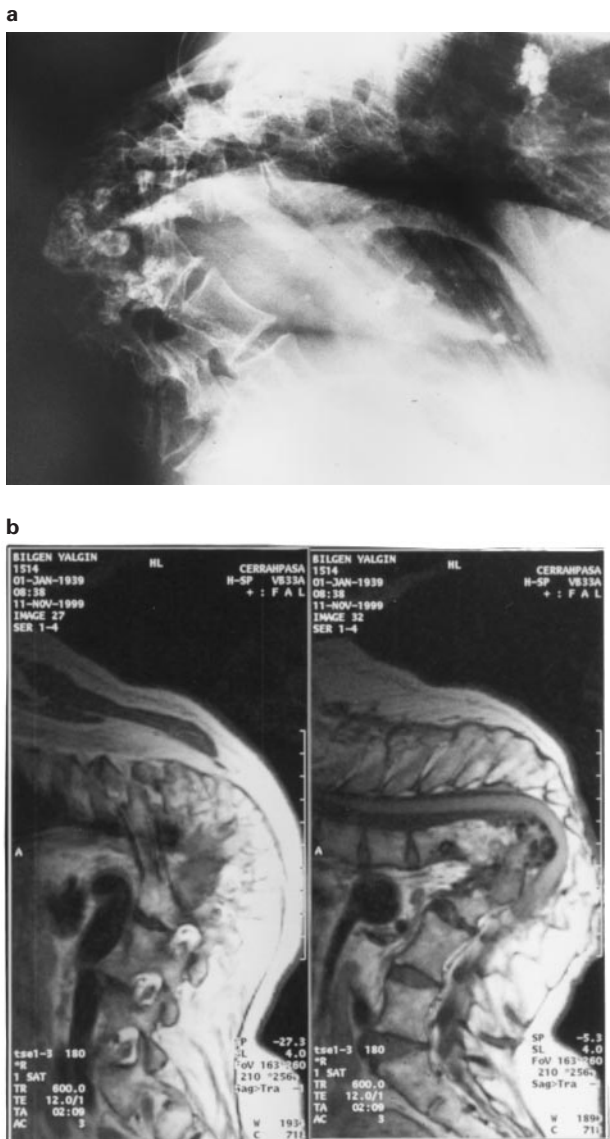


Figure 2 (a) Lateral radiograph of Case 1 at the latest follow-up (173 months after surgery). (b) T1-weighted sagittal MR images of the patient at the latest follow-up showing the position of the graft (left) and clearance of the canal (right)

of 45° or more was complete in 37%, partial in 15%, sensory improvement only occurred in 9%, no recovery in 27% and deterioration in 12%.² According to him, the healing capacity decreased and prognosis was worse in the patients with a kyphosis of 60° or more.

Luk reported that in an unpublished series reviewed in Hong Kong of 60 patients who had previously been treated conservatively, 25 of them developed late onset paraplegia.⁵ Over 65% of them presented with neurological deficit more than 15 years after the onset of the initial disease. The most common symptoms in the middle-aged patients with kyphosis

are slowly progressing weakness and numbness of the lower extremities together with urinary incontinence and unsteady spastic gait. Luk reported that tuberculosis under control by chemotherapy could still recur many years later. Once the signs of neurological dysfunction appear, the treatment must be decompression and even if the adequate decompression can be achieved the results are not guaranteed.

We also believe that conservative measures are not sufficient after the onset of neurological symptoms. A patient with a sharp kyphosis deformity must be treated surgically with anterior decompression and fusion as soon as possible after the initial neurologic symptoms. The deterioration of an already diminished circulation of the spinal cord may worsen the clinical picture. Anterior decompression and fusion must be carried out before this occurs. The slow progression of neurological deterioration must not be a factor to postpone the operative treatment but the patient must be informed about the possible complications and the outcome that can be obtained.

Conclusion

Pott's disease may show recurrence long after the control of the disease with medical therapy. The increase in kyphosis angle may result in narrowing of the spinal canal and deterioration of the medullary circulation. Adequate anterior decompression and grafting is necessary for the treatment of late neurological disturbance but complete recovery may be impossible due to impaired circulation of the spinal cord. The surgical procedures for the treatment of late Pott's paraplegia carry significant risk of neurological complications.

References

- Magid D, Fishman EK. Musculoskeletal infections in patient with AIDS – CT findings. *AJR* 1992; **158**: 603–607.
- Tuli SM. Severe kyphotic deformity in tuberculosis of the spine. *Int Orthop* 1995; **19**: 327–331.
- Tachdjian MO. Tuberculous arthritis. In Tachdjian MO *Pediatric Orthopedics* 2nd edn. WB Saunders Company: Philadelphia, PH 1990, pp 1443–1458.
- Hodgson AR et al. A Clinical study of 100 consecutive cases of Pott's Paraplegia. *Clin Orthop* 1964; **36**: 128–150.
- Luk KDK. Tuberculosis of the spine in the new millennium. *Eur Spine J* 1999; **8**: 338–345.
- Tuli SM. Results of treatment of spinal tuberculosis by 'middle-path' regime. *J Bone Joint Surg* 1975; **57**: 13–23.
- Frankel HL, Hancock DO, Hyskop G. The value of postural reduction in the initial management of closed injuries of the spine with paraplegia and tetraplegia. *Paraplegia* 1969; **7**: 179–192.
- Ditunno JF, Young W, Donovan WH, Creasey G. The international standards booklet for neurological and functional classification of spinal cord injury. *Paraplegia* 1994; **32**: 70–80.
- Rajasekaran S, Shanmugasundaram K. Prediction of the angle of gibbus deformity in tuberculosis of the spine. *J Bone Joint Surg* 1987; **69**: 503–509.



- 10 Hsu LCS, Cheng CL, Leong JCY. Pott's paraplegia of late onset, the cause of compression and results after anterior decompression. *J Bone Joint Surg* 1988; **70**: 534–538.
- 11 Rajasekaran S, Soundarapandian MS. Progression of kyphosis in tuberculosis of the spine treated by anterior arthrodesis. *J Bone Joint Surg* 1989; **71**: 1314–1323.