

ORIGINAL ARTICLE

## Posterior fossa arachnoid cysts

P. ERDİNÇLER, M. Y. KAYNAR, H. BOZKUS & N. ÇIPLAK

*Department of Neurosurgery, Istanbul University, Istanbul, Turkey*

### Abstract

Arachnoid cysts of the posterior fossa are rare lesions that are considered to be mostly congenital in origin. In this article, we retrospectively review 12 patients who underwent surgical treatment for their symptomatic posterior fossa arachnoid cysts. The most common presenting symptoms were gait disturbances and headache. The diagnosis was established on computed tomography or magnetic resonance imaging. Surgery consisted of cyst wall excision with fenestration in nine cases and shunting procedures in three cases. In all cases except one who died, the postsurgical follow-up neuroradiological investigations showed that the cysts had decreased in size, the cerebellum had re-expanded, and if there was preoperative hydrocephalus, the ventricular size was decreased. The follow-up period ranged from 1 to 11 years. All surviving cases are free of symptoms and no arachnoid cysts recurred. The classification, pathophysiology, differential diagnosis and surgical treatment of infratentorial arachnoid cysts are discussed and the relevant literature is reviewed.

**Key words:** *Arachnoid cysts, classification, differential diagnosis, posterior fossa cysts, surgical treatment.*

### Introduction

Intracranial arachnoid cysts are rare central nervous system lesions which account for only 1% of all intracranial masses. One-quarter to one-third of all arachnoid cysts involve the posterior fossa.<sup>1–3</sup> Posterior fossa arachnoid cysts produce a range of clinical presentations. The clinical symptoms result from hydrocephalus and compression of the underlying structures. Differentiation of the posterior fossa arachnoid cysts from other cystic and/or cyst like lesions is essential for proper treatment planning. Treatment of symptomatic cysts consists of cyst wall excision with fenestration or cystoperitoneal (CP) shunting. Throughout the literature controversies exist about the classification, pathophysiology, differential diagnosis and treatment of arachnoid cysts.

In this report, we retrospectively review 12 patients with symptomatic posterior fossa arachnoid cysts who underwent surgical treatment in our department, and discuss the classification, pathophysiology, differential diagnosis and surgical treatment of these malformations.

### Patients and Methods

Between January 1983 and December 1996, 12 patients with infratentorial arachnoid cysts, were treated surgically in the Neurosurgery Department

of Cerrahpaşa Medical School. These cysts represented 13% of 93 intracranial arachnoid cysts diagnosed during the study period. There were six males and six females, whose ages at the time of clinical presentation ranged from 2 months to 59 years. Clinical information was obtained by review of the patient records, operative reports and follow-up data were obtained via records of outpatient clinic visits. All patients had at least one computed tomography (CT) or magnetic resonance imaging (MRI) at 6–12 months postoperatively and were followed-up clinically for 1–11 years.

### Results

#### *Clinical presentation*

The presenting complaints were instability when walking and headache in most of the cases. Neurological findings were related to the posterior fossa in most of the cases. Macrocephaly was a common findings in the infant group. The duration of symptoms before diagnosis was usually short. Case 11 was in coma at admission to the hospital. Table I summarizes the clinical pictures.

#### *Neuroradiological findings and locations*

The diagnosis of arachnoid cyst was made by CT in seven cases, by MRI in two cases, and by CT and

Correspondence to: Pamir Erdinçler M.D., PK 19, 34312, K.M. Paşa, Istanbul, Turkey. Tel: (90)21252 94590. Fax: (90)2122732477. E-mail: oymakas@superonline.com.

Received for publication 28th October 1997. Accepted 28th April 1998.

TABLE I. Clinical features, outcome of surgery, and follow-up periods of 12 patients with infratentorial arachnoid cysts

No.	Age (year)/sex	Complaints and duration	Neurological findings	Cyst location & hydrocephalus	Surgery	Outcome	Follow-up period
1	26/F	Headache, nausea, vomiting (1 month)	papilloedema	Retrocerebellar, mild hydrocephalus	Cyst excision	Cyst and ventricular sizes decreased, no complaints	6 years
2	31/F	Instability when walking, vertigo (1 year)	Gait ataxia, nystagmus	Retrocerebellar	Cyst excision	Cyst size decreased, no complaints	11 years
3	38/F	Headache, amnesia (5 years)	Papilloedema	Supracerebellar, mild hydrocephalus	Cyst excision	Ventricular size decreased, small residual cyst, no complaints	5 years
4	59/M	Headache, vertigo, instability when walking, hypoacusia in left ear, hypaesthesia in left face (3 months)	Gait ataxia, left V, VIII th nerve palsy	Left CPA	Cyst excision	Small residual cyst at the CPA, no complaints	7 years
5	26/M	Headache, instability when walking, muscle wasting (3 weeks)	Gait ataxia, nystagmus, dysmetria	Retrocerebellar, mild hydrocephalus	Cyst excision	Cyst and ventricular sizes decreased, no complaints	Lost to follow-up 3 years after the surgery
6	53/M	Instability when walking, nausea, headache (3 months)	Left VIIIth nerve palsy, gait ataxia, left dysmetria	Right intracerebellar, mild hydrocephalus	Cyst excision	Cyst and ventricular sizes decreased, no complaints	9 years
7	33/F	Tinnitus in right ear (4 years)	Hypoacusia in right	Right CPA	Cyst excision	Cyst disappeared, no complaints	7 years
8	36/M	Headache, instability when walking (6 months)	Gait ataxia, papilloedema	Retrocerebellar, mild hydrocephalus	Cyst excision	Cyst and ventricular sizes decreased, no complaints	2 years
9	6 months/M	Macrocephaly	Bulging fontanel	Retrocerebellar, severe hydrocephalus	Y connected VP and CP shunt	Cyst and ventricular sizes decreased, no complaints	1 years
10	7 months/M	Macrocephaly	Bulging fontanel	Supracerebellar, severe hydrocephalus	VP and CP shunt	Ventricular size decreased, cyst disappeared, no complaints	1,5 years
11	1/F	Macrocephaly, vomiting, drowsiness, convulsions, dysphagia (1 week)	Impaired consciousness, bulging fontanel, sunset eyes	Retrocerebellar, severe hydrocephalus	EVD + Cyst excision	—	Died after surgery
12	2 months /F	Macrocephaly	Sunset eyes, bulging fontanel	Retrocerebellar, severe hydrocephalus	VP and CP shunt	Cyst and ventricular sizes decreased, no complaints	3 years

\*Abbreviations: EVD: external ventricular drainage; CPA: cerebello-pontine angle.

MRI in three cases. The location was retrocerebellar in seven, supracerebellar in two, in the cerebellopontine angle (CPA) in two and intracerebellar in one. Arachnoid cysts appeared on CT as uncalcified, low-density, extra-axial masses with regular borders that did not enhance with the administration of contrast medium (Fig. 1). The fourth ventricle and vermis were visualized by axial

CT or MRI in all cases except Case 10, where the CT was initially misinterpreted as a communicating hydrocephalus (Fig. 2A). A CT 3 months after insertion of a ventriculoperitoneal (VP) shunt revealed an isolated cyst at the tentorial incisura and bilateral subdural haematomas. MRI showed a huge cyst filling the posterior fossa (Fig. 2B,C). The cyst was diagnosed as a supracerebellar arachnoid cyst

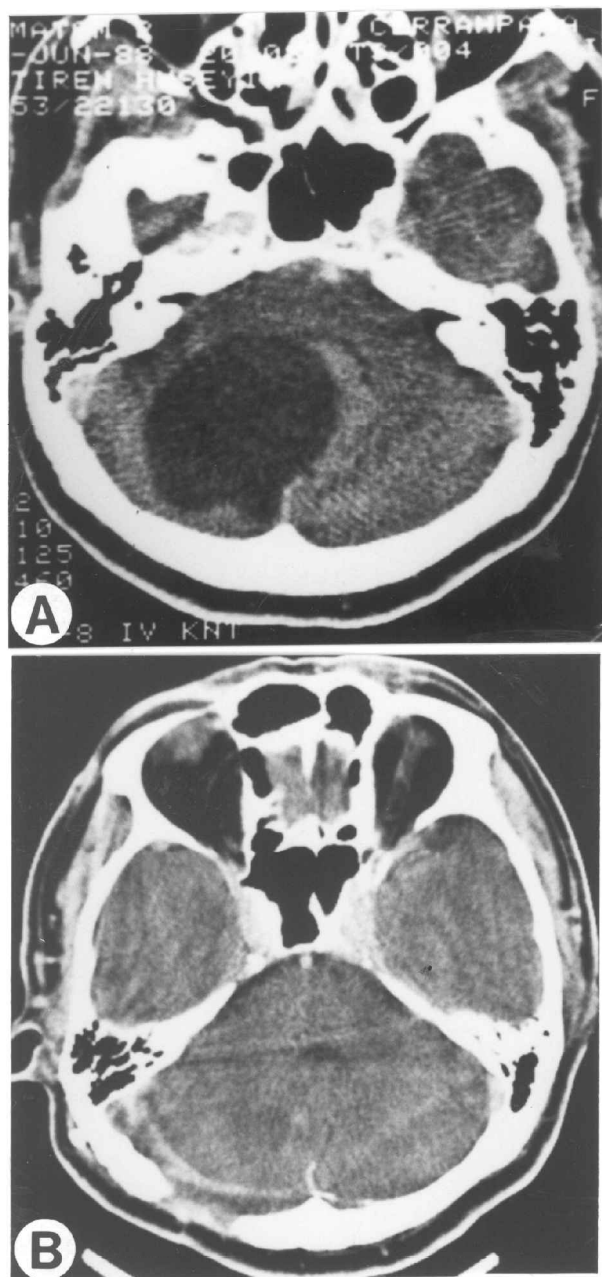


FIG. 1. (A) Preoperative CT scan with contrast of case 6 shows an intracerebellar arachnoid cyst compressing the 4th ventricle. (B) Six months after cyst wall excision, on postcontrast CT scans, the cyst has almost entirely disappeared and the fourth ventricle is now well visualized.

compressing the fourth ventricle. In one case, metrizamide CT ventriculography was performed in order to identify any communication between the cyst and fourth ventricle (Fig. 3A). In none of the cases reviewed did plain skull radiographs, CT or MRI studies suggest an elevation of the torcula an enlargement of the posterior fossa or localized thinning of the occipital bone. On MRI, the contents of arachnoid cysts had the same signal characteristics as cerebrospinal fluid (CSF) on both T1-weighted and T2-weighted images. No peripheral oedema was seen even in T2-weighted images.

### Surgical treatment and outcome

Surgery consisted of cyst wall excision with fenestration into the fourth ventricle or surrounding subarachnoid cisterns in nine cases and shunting procedures in three cases. In these nine cases, the cyst wall histologically resembled the arachnoid in structure. A VP shunt was first inserted in case 10 and 3 months later a CP shunt was done (Fig. 2D). In case 9, a Y connected VP and CP shunt was inserted at the same time because of the non-communicating nature of the cyst (Fig. 3B). Case 11 presented with abrupt neurological deterioration before surgery. An external ventricular drainage (EVD) was inserted urgently, thereafter the posterior fossa arachnoid cyst was excised. However, the patient died on the fourth postoperative day. A VP shunt was inserted at 2 months of age in case 12 as the first treatment (Fig. 4a). The child showed normal psychomotor development until 3 years of age. MRI performed at this time revealed severe compression of the cerebellum and the brain stem by the retrocerebellar arachnoid cyst (Fig. 4B). A CP shunt was then inserted. 1 month later, moderate re-expansion of the cerebellum was seen on control MRI (Fig. 4C).

In all surviving cases, control CT or MRI scans showed that the cysts had decreased in size, the cerebellums re-expanded, and if there was preoperative hydrocephalus, the ventricular size had decreased (Fig. 5). There was no case in the cystectomy group who needed VP shunting after treatment. The bilateral subdural haematomas and the huge supracerebellar arachnoid cyst resolved completely after cystoperitoneal shunting in case 10 (Fig. 2D). The clinical follow-up periods ranged from 1 to 11 years. All cases are free of symptoms and no arachnoid cyst recurred (Table I).

### Discussion

The posterior fossa is the second most common location of arachnoid cysts after the middle cranial fossa.<sup>2-4</sup> In paediatric series, the incidence of posterior fossa cysts among intracranial arachnoid cysts is given between 20 and 30%.<sup>3,5</sup> Our 13% incidence probably reflects the adult preponderance in our practice.

### Clinical presentation and pathophysiology

It is not known how exactly arachnoid cysts grow, but when they give rise to symptoms, these are usually caused by local compression of the surrounding nervous structures and/or obstructive hydrocephalus.<sup>6,7</sup> In the light of the follow-up data of our case 12, we know that the retrocerebellar arachnoid cyst gradually compressed the cerebellum and the brain stem during 3 years of follow-up demonstrating the gradual increase in the size of the cyst despite of a functioning VP shunt. Three theories exist for explaining the filling of the cysts by CSF: The ball-valve mechanism,<sup>8</sup> active secretion of CSF through

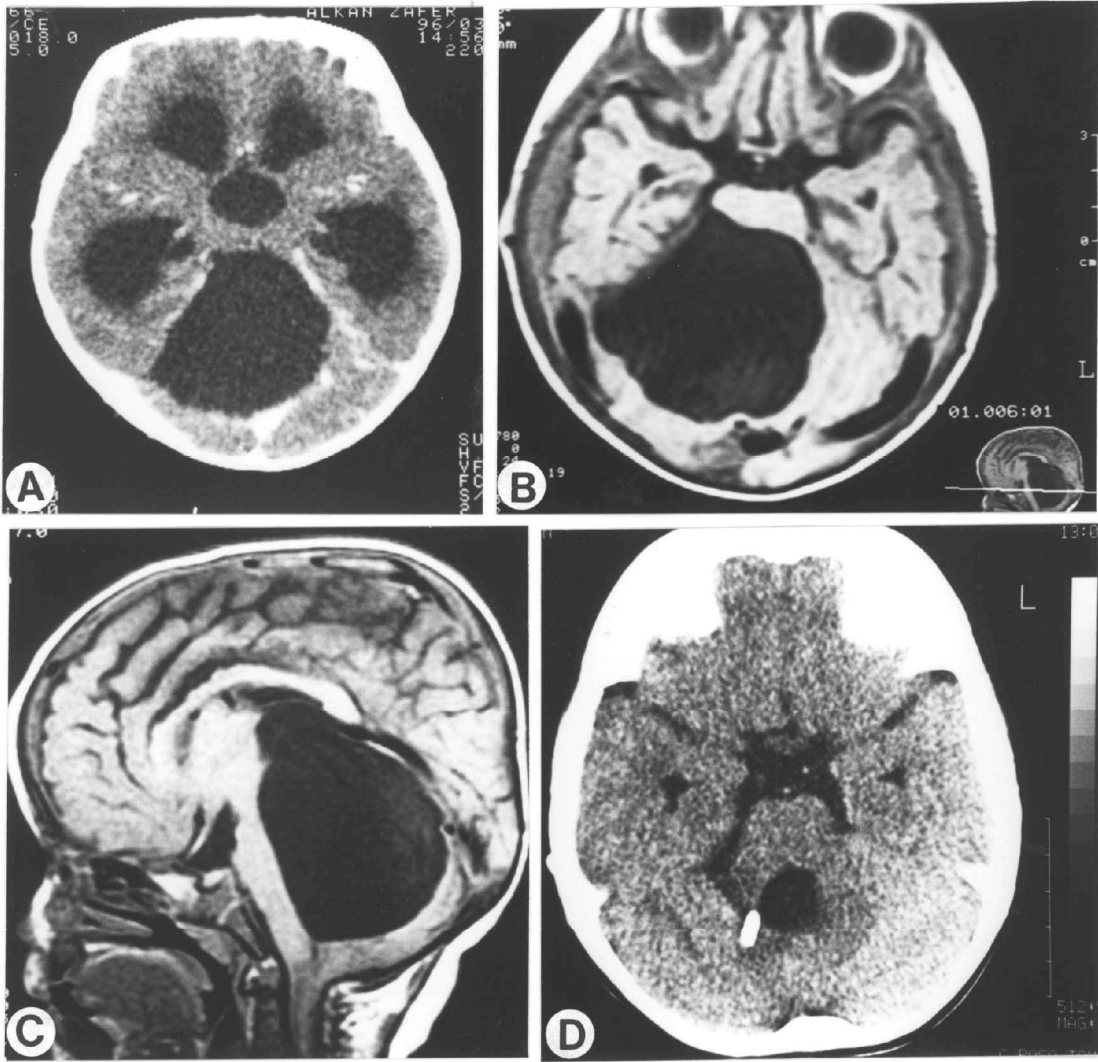


FIG. 2. Case 10. (A) Axial CT scan shows massive dilation of the third and lateral ventricles. The arachnoid cyst lies at the tentorial incisura. (B) Three months after insertion of a VP shunt, T1-weighted axial MRI scan shows bilateral subdural haematomas, and an enlarged arachnoid cyst at the tentorial incisura. (C) T1-weighted mid-sagittal MRI scan shows the supracerebellar arachnoid cyst filling the posterior fossa. Note that despite the size of the cyst, the posterior fossa is not enlarged and the torcula is normally positioned. (D) CT scan 1 year after CP shunting, demonstrates the disappearance of the bilateral subdural hematomas and arachnoid cyst.

the walls of the cysts<sup>9</sup> and filling of the cyst by osmotic gradient.<sup>10</sup> The anatomical communication may also be intermittent.<sup>2</sup>

Sometimes, a minor head injury can provoke the onset of symptoms. Galassi *et al.*<sup>2</sup> suggested that the clinical picture is one of long duration with an episodic course in adults. Some complaints, such as headache or vertigo can have a long history reflecting a chronic increased intracranial pressure, but the duration of signs and symptoms before diagnosis, such as gait ataxia or cranial nerve palsy was usually short in our cases. If the cysts are associated with other central nervous system developmental abnormalities or if a history of a traumatic delivery or an inflammatory process is present in the aetiology, psychomotor retardation is usually seen.<sup>2,11</sup> We did not detect any inflammatory or traumatic aetiology in the history of our patients, nor any association of any other severe central nervous system developmental abnormalities. None of our patients had psychomotor retardation.

As suggested by Barkovich *et al.*,<sup>7</sup> posterior fossa CSF collections can result from abnormal development of the cerebellum or fourth ventricle or from formation of arachnoid cysts arising as a result of anomalous splitting and duplication of the endoneurium during neural tube folding as in true arachnoid cyst at other sites in the brain.<sup>4,12,13</sup>

Because of the hydrocephalus which is frequently associated with infratentorial arachnoid cysts some authors have ascribed the pathogenesis either to defective CSF absorption mechanisms<sup>14</sup> or to a developmental block of the cisterns rostral to the cyst,<sup>15,16</sup> rather than merely to mechanical factors. In all of our four paediatric cases macrocephaly was the alerting sign of a posterior fossa arachnoid cyst, though in the majority of adult cases the presenting complaints were related to the posterior fossa. In five adult cases with associated mild hydrocephalus, a decrease in ventricular size followed simple partial cyst excision. Thus, it seems that in adult cases mechanical obstruction of

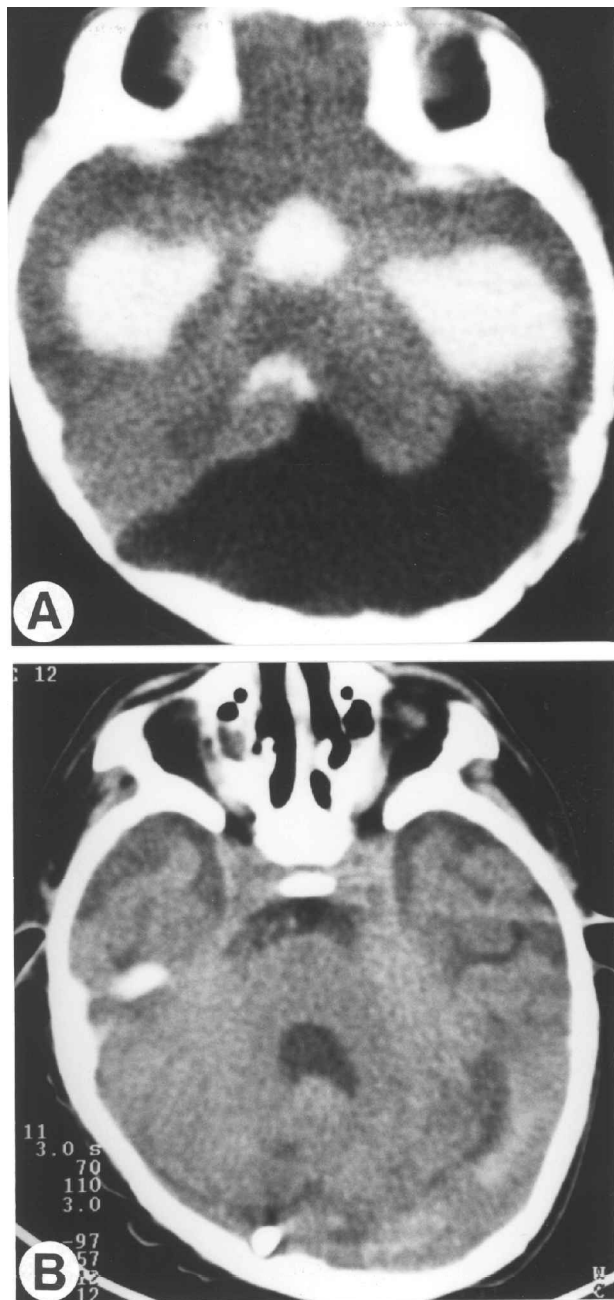


FIG. 3. Case 9. (A) A non-communicating retrocerebellar posterior fossa arachnoid cyst is seen on axial CT scans after intraventricular injection of contrast via the bregmatic fontanel. (B) A reduction in cyst and ventricular size is seen after insertion of a Y connected ventriculo-cysto-peritoneal shunt.

the CSF circulation pathways by the cyst may be the main cause of hydrocephalus. All of the paediatric cases presented with a rapid progression of hydrocephalus. All of them but the one who died following cyst excision, were treated with VP and CP shunting.

*Classification*

Many proposed classification systems exist for posterior fossa cysts. Little *et al.*<sup>17</sup> grouped infratentorial arachnoid cysts according to their location. A topographic classification was proposed by Vaquero

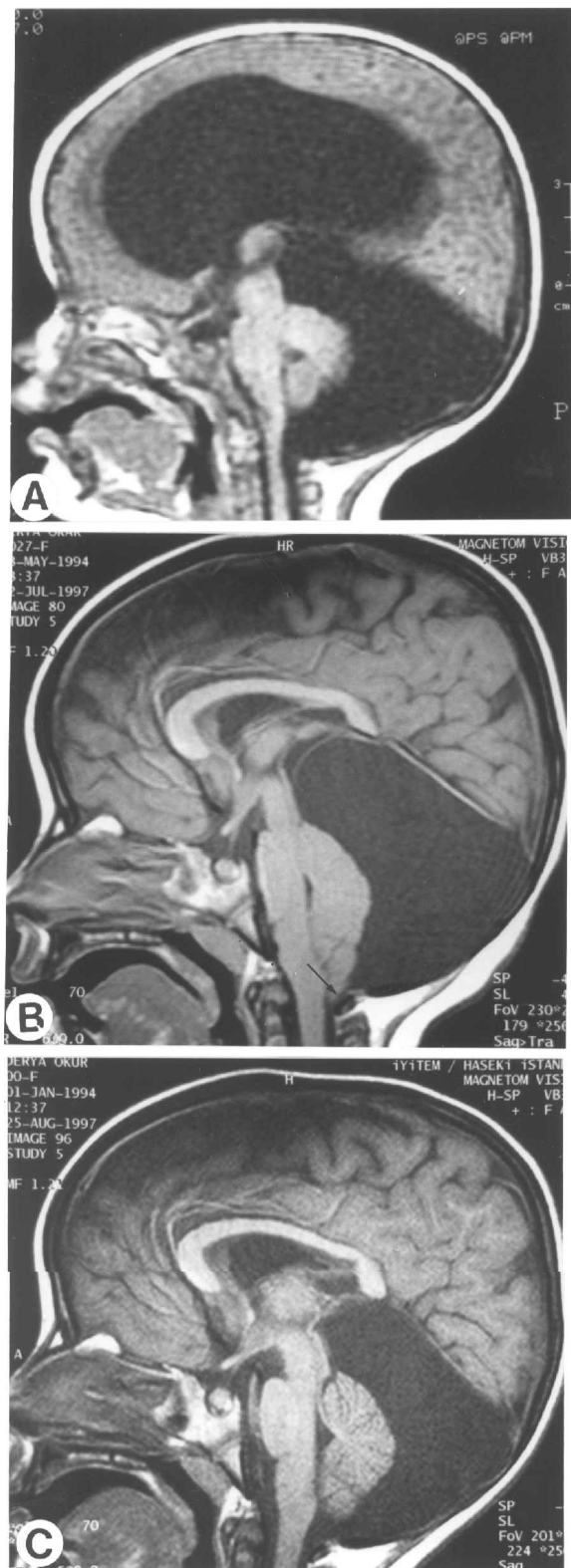


FIG. 4. Case 12. (A) T1-weighted midsagittal MRI scan at 2 months of age shows retrocerebellar arachnoid cyst and marked non-communicating hydrocephalus. (B) 3 years after insertion of a VP shunt, the ventricular size was decreased, but the cerebellum and the brain stem were severely compressed by the enlarged cyst. There was a moderate herniation of the cerebellar tonsils below the foramen magnum (arrow). (C) One month after insertion of a CP shunt, the compression of the cerebellum and the brain stem has disappeared. Note that the posterior fossa is not enlarged and the torcular herophilli is normally positioned.

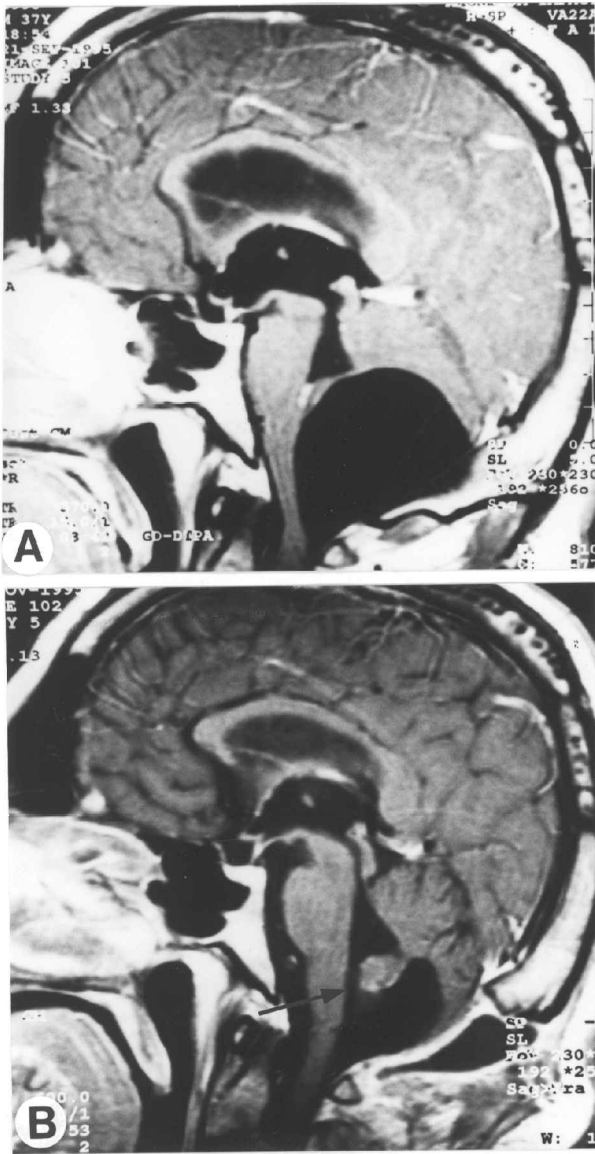


FIG. 5. Case 8. (A) Preoperative T1-weighted mid-sagittal MRI scan shows a retrocerebellar arachnoid cyst compressing the fourth ventricle. There was no elevation of the torcula and no enlargement of the posterior fossa. (B) After cyst wall excision and fenestration into the fourth ventricle, the cyst has decreased in size. The communication established between the cyst and the fourth ventricle is seen (arrow).

*et al.*<sup>18</sup> Arai and Sato<sup>11</sup> classified all posterior fossa cysts depending on the location and extension. We included our two cases of supracerebellar cyst in this study, because they were mainly localized in the posterior fossa with extension superiorly and they were approached operatively through the posterior fossa.

In recent reports, great importance is attributed to the formation of the floor of the fourth ventricle and vermis.<sup>7,11</sup> Barkovich *et al.*<sup>7</sup> define posterior fossa arachnoid cysts as all discrete posterior fossa CSF collections that are clearly separate from the fourth ventricle and vallecula. They categorize Dandy-Walker malformation, Dandy-Walker variant and mega-cisterna magna as a separate continuum of

developmental anomalies of the posterior fossa.<sup>7</sup> We are in agreement with them. We think that a true arachnoid cyst has a congenital origin, but is not associated with other developmental anomalies of the cerebrum and cerebellum. Based on clinical and neuroradiological features, they must be classified as a separate entity.<sup>11</sup>

#### Differential diagnosis

The differential diagnosis of posterior fossa arachnoid cysts includes any cystic lesion of the posterior fossa, such as cerebellar cystic astrocytomas, cystic haemangioblastoma, hydatid cysts, abscesses, epidermoid or dermoid tumours. There are also a few reports in the literature in which an epithelial, gliependymal or choroidal cyst was diagnosed histologically.<sup>11,19,20</sup> The characteristic appearance of an uncalcified, low-density, extraaxial mass with regular borders that do not enhance with administration of contrast medium make the differential diagnosis from neoplastic or infectious disorders simple in most cases. Epidermoid tumours are slightly hyperintense on proton density-weighted MRI images, encase and engulf arteries and cranial nerves, whereas arachnoid cysts displace adjacent structures.<sup>21</sup>

The main problem exists in differentiating arachnoid cysts from the Dandy-Walker malformation, vermian-cerebellar hypoplasia and mega cisterna magna.<sup>22</sup> In our study, the key features for the distinction were visualization of the fourth ventricle and vermis on CT or MRI, demonstration of the torcula and its sinuses normally positioned, and a normal-sized posterior fossa. In all cases, the posterior fossa was normal-sized, the torcula was normally positioned and the fourth ventricle and vermis were seen on CT or MRI except case 10. As previously described this case was first misdiagnosed as a communicating hydrocephalus, although preoperative CT were highly suggestive of a posterior fossa cyst. The non-communicating nature of the cyst and the significance of a normally positioned torcula were appreciated when MRI was available. The fourth ventricle and brain stem were severely compressed by the cyst, but the vermis was intact.

The significance of the position of the torcula and the size of the posterior fossa are not yet clearly defined in the differential diagnosis of posterior fossa cysts. It is well known that in the Dandy-Walker complex, there is a large posterior fossa with elevation of the torcula and its sinuses.<sup>1</sup> However, there are also many reports which describe the same morphological characteristics with posterior fossa arachnoid cysts.<sup>2,18,23</sup> Nevertheless, in none of the six cases of posterior fossa arachnoid cyst reported by Barkovich *et al.*,<sup>7</sup> was there an enlarged posterior fossa or an elevated torcula. We think that a normal-sized posterior fossa with a normally positioned torcula are the key features of this differentiation

even in infants. Our four paediatric cases under 1 year of age accorded with this observation.

Angiographical evidence of arteriovenous dissociation over the surface of the brain is proposed for differentiating these cysts from the Dandy–Walker malformation and a mega cisterna magna.<sup>11</sup> However, the development of MRI may obviate the need for angiography.<sup>24</sup>

The wide variation in the appearance of the cerebellar vermis seen on sagittal MRI, the expansion and invagination of the arachnoid wall, marked compression capacity of the cyst to the surrounding structures can make the diagnosis of an arachnoid cyst difficult in some cases. Two cases reported by Wolpert *et al.*<sup>25</sup> exemplify the difficulties in achieving a final diagnosis even after surgery. In their cases, the preoperative radiological findings of the posterior fossa anatomical structures and arachnoid cysts were completely changed after surgery. This can be due to the growth capacity of both cerebrum and cerebellum at an early age, but also can reflect potential invagination of arachnoid walls into the subarachnoid spaces and fourth ventricle.

We think that distinction between a communicating and non-communicating cyst is not always necessary. In cases of mega-cisterna magna, if the posterior fossa is normally sized, and if there is no elevation of the tentorium and the torcula, filling of the cyst by contrast makes a clear distinction between an arachnoid cyst and a mega cisterna magna.<sup>11,26</sup> We had no cases in this study that needed differentiation from a mega cisterna magna. In a single case in which we performed CT ventriculography, we decided to insert a Y connected ventriculo-cystoperitoneal shunt because of the non-communicating nature of the cyst.

If CT cisternography reveals early or late filling of the cyst by contrast, it shows a communication from the subarachnoid space to the cyst, but does not give any information if there is a communication from the cyst to the subarachnoid space. We believe that, except for some selected cases, knowing the existence of any communication between the cyst and the subarachnoid spaces is not really helpful and reliable for diagnosis and surgical treatment.

#### *Surgical treatment*

The debate which exists over the surgical treatment of supratentorial arachnoid cysts by shunting procedures or cystectomy exists also for the posterior fossa.<sup>3</sup> We preferred in most of our cases excision of the cyst wall alone so as to avoid shunt dependence. In all of the cases where we performed cyst excision, successful results were obtained with a single operation and no recurrence was observed. On the other hand, in our three cases that were treated only by shunting procedures, the results were also successful. Our mortality in case 11 was related to the preoperative poor neurological status rather than a complication of surgery. Our results were satisfactory with both surgical treatment modalities.

## Conclusions

We suggest that, as a rule, if there are no developmental anomalies associated with a posterior fossa arachnoid cyst, and if the symptomatology is only of a space occupying lesion in the posterior fossa, and if after surgery, the cyst decreases in size, the cerebellum and vermis re-expand and relief of symptoms is provided then it is questionable whether these cases have a congenital origin, or whether they are really developmental anomalies. Elevation of the torcula and its sinuses, an enlarged posterior fossa and clear developmental anomalies of the rhombencephalic roof are features that suggest a less favourable prognosis with surgical treatment than for a true arachnoid cyst.

Mechanical obstruction at the level of fourth ventricle or aqueduct of Sylvius is the major underlying cause of hydrocephalus in adult patients with posterior fossa arachnoid cysts and this is preventable with the restoration of CSF circulation pathways by cyst excision without the need for shunting. On the other hand, in paediatric patients, the hydrocephalus is more severe and successful results can be obtained with shunting procedures alone.

## References

- Altman NR, Naidich TP, Braffman BH. Posterior fossa malformations. *AJNR* 1992;13:691–724.
- Galassi E, Tognetti F, Frank F, Fagioli L, Nasi MT, Gaist G. Infratentorial arachnoid cysts. *J Neurosurg* 1985;63:210–17.
- Raffel C, McComb JG. To shunt or to fenestrate: which is the best surgical treatment for arachnoid cysts in pediatric patients. *Neurosurgery* 1988;23:338–42.
- Rengachary SS, Watanabe I. Ultrastructure and pathogenesis of intracranial arachnoid cysts. *J Neuropathol Exp Neurol* 1981;40:61–83.
- Ciricillo SF, Cogen PH, Harsh GR, Edwards MSB. Intracranial arachnoid cysts in children: A comparison of the effects of fenestration and shunting. *J Neurosurg* 1991;74:230–5.
- Becker T, Wagner M, Hoffmann E, Warmuth-Metz M, Nadjmi M. Do arachnoid cysts grow? A retrospective CT volumetric study. *Neuroradiology* 1991;33:341–5.
- Barkovich AJ, Kjos BO, Norman D, Edwards MS. Revised classification of posterior fossa cysts and cyst-like malformations based on the results of multiplanar MR imaging. *AJNR* 1989;10:977–88.
- Smith RA, Smith WA. Arachnoid cysts of the middle cranial fossa. *Surg Neurol* 1976;5:246–52.
- Go KG, Houthoff HJ, Blaauw EH. Arachnoid cysts of the Sylvian fissure. Evidence of fluid secretion. *J Neurosurg* 1984;60:803–13.
- Dyck P, Gruskin P. Supratentorial arachnoid cysts in adults: a discussion of two cases from a pathophysiologic and surgical perspective. *Arch Neurol* 1977;34:276–79.
- Arai H, Sato K. Posterior fossa cysts: clinical, neuro-radiological and surgical features. *Childs Nerv Syst* 1991;7:156–64.
- Krawchenko J, Collins GH. Pathology of an arachnoid cyst. *J Neurosurg* 1979;50:224–8.
- Harsh GR, Edwards MSB, Wilson CB. Intracranial arachnoid cysts in children. *J Neurosurg* 1986;64:835–42.

- 14 Di Rocco C, Caldarelli M, DiTrapani G. Infratentorial arachnoid cysts in children. *Childs Brain* 1981;8:119–33.
- 15 Harrison MJG. Cerebral arachnoid cysts in children. *J Neurol Neurosurg Psychiatry* 1971;34:316–23.
- 16 Robinson RG. Congenital cysts of the brain: arachnoid malformations. *Prog Neurol Surg* 1971;4:133–74.
- 17 Little JR, Goomez MR, MacCarty CS. Infratentorial arachnoid cysts. *J Neurosurg* 1973;39:380–6.
- 18 Vaquero J, Carillo R, Cabezudo JM, Nombela L, Bravo G. Arachnoid cysts of the posterior fossa. *Surg Neurol* 1981;16:117–21.
- 19 Koto A, Horoupian DS, Shulman K. Choroidal epithelial cyst. Case report. *J Neurosurg* 1977;47:955–60.
- 20 Jamjoom A, Jamjoom ZA, Griffiths D, Moss T, Coakham H. Cerebellopontine angle epithelial cyst. A case report. *Neurosurg Rev* 1993;16:67–70.
- 21 Quint DJ. Retroclival arachnoid cysts. *AJNR* 1992; 13:1503–4.
- 22 Kollias SS, Ball WS Jr, Prenger EC. Cystic malformations of the posterior fossa: differential diagnosis clarified through embryologic analysis. *Radiographics* 1993; 13:1211–31.
- 23 La Torre E, Fortuna A, Occhipinti E. Angiographic differentiation between Dandy–Walker cyst and arachnoid cyst of the posterior fossa in newborn infants and children. *J Neurosurg* 1973;38:298–308.
- 24 Rock JP, Zimmerman R, Bell OW, Fraser RAR. Arachnoid cysts of the posterior fossa. *Neurosurgery* 1986; 18:176–9.
- 25 Wolpert SM, Scott RM, Runge VM, Kwan ESK. Difficulties in diagnosing congenital posterior fossa fluid collections after shunting procedures. *AJNR* 1987; 8:653–6.
- 26 Hough DR, Mengel MB, Malik AH. Mega cisterna magna: diagnosis using metrizamide computed tomographic cisternography. *Neurosurgery* 1982;11;260–2.