

THE EVALUATION OF STABILITY OF POSTERIOR FIXATION IN THE EXPERIMENTAL MODEL OF DISCOLIGAMENTOUS INJURY

Fatma ÖZLEN MD.*

Murat HANCI MD.*

Mustafa UZAN MD.*

Hatice KALAVA MD.**

Ali Çetin SARIOĞLU MD.*

Cengiz KUDAY MD.*

ABSTRACT:

The aim of the experimental study was to assess stabilization of the spinal column provided by posterior fixation using triple wire in total discoligamentous injury of the cervical vertebrae. To achieve this, functional C₄-C₅ spinal units taken from 6 month old sacrificed calves weighing 100 kgs were used. The amount of force which caused a unit displacement under flexion, extension and axial loads was separately calculated in the control group of intact subjects, in the lesion group of unstable subjects and in the treatment group of subjects whose posterior fixation was carried out post creation of an instability. The in-vitro stability provided by posterior fixation as a technique of internal stabilization was discussed with respect to the statistical significance of the data.

Key Words: Discoligamentous injury, posterior fixation, stability

INTRODUCTION

There are few disorders or types of trauma which are more distressing and threatening to life and the quality of life than cervical injury. The cervical region of the spinal cord is the site most frequently exposed to trauma, with an incidence highest in the younger age brackets (4). Though our first knowledge on this subject goes back 5000 years, spinal surgery was first performed with decompression of fragments compressing the medulla by James in 1745, and by Heister in 1768. Using posterior cerclage wire fusion, the first intervention which provided spinal stability and which prevented progressive kyphosis was carried out by Hadra in 1891. Rogers established modern principles and techniques of subaxial posterior fusion in 1942. Robinson and Southwick performed posterior facet fusion in 1960, Roy Camille instituted the posterior plate fusion in 1972, whereas Callahan reported the solid fusion by segmenter instrumentation in 1977. Daub-Plate and Halifax designed the interlaminar clamp in 1984, Bohlman defined the triple wire technique in 1985, and Ulrich and Mayer designed the hook-plate in 1987. Different methods of internal stabilization, posterior and/or anterior procedures of stabilization, have been employed for the treatment of unstable functional units of the cervical spine. The present

study was designed to evaluate the adequacy of triple wire technique in providing stability in cases of discoligamentous injury of cervical vertebrae.

MATERIAL AND METHOD

Fifteen spine specimens (C₁-C₇) obtained from 6 month old calves weighing 100 kg, having been detached from the muscles were wrapped in plastic bags and freeze stored at -20 degree °C. On the day of testing, the specimens were thawed and the C₄₋₅ functional spinal unit (FSU) was separated from the specimen. The FSU were fixed in the frame with screws and the measurement were done by HBM-mk static bridge. The force was applied to the gravity center of the vertebrae at an accelerated rate of 50 newton per second for the axial loading. Unloading at the sum total of 300 N, the displacements measured over the measurement. Repeating this procedure 5 times for each subject, the last measurement was taken into consideration. The same procedures, either from 2 cm lateral of the gravity center of the vertebra in lateral bending loads or from 2 cm behind the gravity center of the vertebra in extension loads, were repeated. The force attained in the last load which caused a 1 cm displacement in the measurement bowstring was rated as epsilon. In flexion testing, the same procedures were repeated by placing the force application pen 2 cm in front of the vertebra's center of gravity, after the meas-

* Istanbul University Cerrahpaşa Medical Faculty Department of Neurosurgery, Aksaray, Istanbul/TURKEY.

** Istanbul Technical University Faculty of Mechanical Engineering, Güneşsuyu, Istanbul/TURKEY.

urement bowstring was placed on the spinous process. It was detected that the C₄₋₅ spinal unit remained within the limits of elastic deformation following the unloading done after each enforcement. The displacements were expressed in millimeters, and the force was defined in Newton. In the subjects of the lesion group, severing the supraspinous ligament, the interspinous ligament, ligamentum flavum, capsular ligament annulus fibrosus, PLL (posterior longitudinal ligament) and ALL (anterior longitudinal ligament), the spinal unit was made unstable and then the other procedures defined previously were applied. The treatment group consisted of 5 unstable subjects whose C₄₋₅ posterior fixation was maintained using 1.2 mm stainless steel wires according to Bohlman's triple wire technique. The same procedure for the control and lesion groups was repeated and the fusion was checked by direct radiographs. For each subject, the specimens were kept wet using 0.9% NaCl during the procedures which did not last more than six hours.

RESULTS

The results of the experiment were evaluated in the control, lesion and treatment groups the ANOVA method using SPSS/PC+ software. The limit of statistical significance was accepted as $p < 0.05$. When the control group was compared to the lesion group, the displacement was found to be 2.01 mm in the control group and 2.56 mm in the lesion group. This did not show any statistical significance with $F = 1.916$ and $p < 0.204$ in the case of axial loading. In the case of lateral bending in the lesion group, the results were excluded from the evaluation because the system showed an extensive displacement after a 100 N loading, therefore loading of up to 300 N was not attempted. The force, capable of creating a 1 cm displacement in flexion was 607.67 N in the control group, 70 N in the lesion group and this was found to be very significant with $F = 52.438$ and $p < 0.001$. In extension, these values were 470.30 N in the control group, 51.50 N in the lesion group and these were very significant with $p < 0.0001$. When the lesion group was compared with the treatment group in the axial loading, the displacement value which was 2.56 mm in the lesion group, and which was 1.51 mm in the treatment group was found to be insignificant with $F = 3.083$ and $p > 0.05$. One cm displacement in flexion was provided by 70 N in the lesion group, while it was 1883.5 N in the treatment group and this showed a great significance with

$F = 40.267$ and $p < 0.0001$. In the extension measurements, these values were 51.50 N in the lesion group, 562 N in the treatment group and this was found significant ($p = 0.003$). The comparison between the control group and the treatment group is summarized in Figure 1. In flexion loading, the force which caused 1 cm displacement was 607.67 N in the control group, while it was 1883.5 N in the treatment group; it was found to be significant as $p = 0.003$. In vivo stability provided by posterior fixation was significantly stronger in the intact subjects which formed the control group in flexion loading (Figure 1). The force which caused 1 cm displacement in extension loading was 470.3 N in the control group, and 562 N in the treatment group ($p = 0.536$). The statistical insignificance showed that posterior fixation provided a resistance equivalent to intact subjects under extension loading (Figure 2). In axial loading, the displacement caused by 300 N was 2.01 mm in the control group, and 1.51 mm in the treatment group, the difference was insignificant ($P = 0.511$). This was interpreted as posterior fixation reached the intact stability value (Figure 3).

DISCUSSION

Cervical spinal instability, when not treated, causes a progressive neurological deficit together with kyphosis. Another complication which occurs is pseudarthrosis. The fusion of unstable cervical vertebra in order to prevent these complications as well as internal stabilization techniques such as anterior and/or posterior fixation are employed for this reason. Biomechanical testing is necessary to evaluate the activity of the instruments utilized in these treatment techniques (1). Sutterlin and his colleagues first used calf vertebrae for the cervical biomechanics researches, (15) as the structural and spinal osteoligamentous parts of calf vertebrae have been found suitable for biomechanical testing (13). Coe et al reported the advantages and disadvantages of calf and human cervical specimens in *in vitro* biomechanical testing and the consistency of biomechanical implanting tests in these subjects (3). Therefore fresh young calf vertebrae were used in our study; specimens were wrapped in plastic bags to be kept at -20 degree °C so that the biomechanical features of the ligaments and bone structures did not undergo any deterioration (12).

According to Allen et al the most widespread type of cervical injury has been (2) third degree destructive flexion or bilateral facet dislocation and in each three

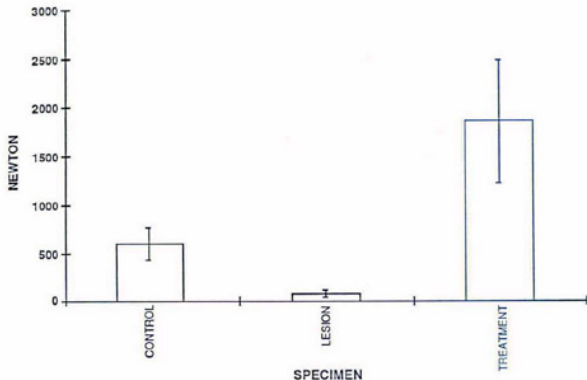


Figure 1. Comparison of groups under flexion forces

columns, instability has been present. We maintained instability by dissecting interspinous -supraspinous ligaments, facet articulations, ligamentum flavum, PLL, annulus fibrosus and ALL. There are controversial opinions in the selection of anterior, posterior or combined interventions in the case of such injuries. Ulrich et al (16) created discoligamentous injury in the C₅ FSU of the human cadaver, and showed that anterior fixation is effective in the treatment of it, while posterior fixation is stronger than anterior fixation in those cases. Coe (3), studied anterior and posterior fixation techniques in subjects who have three column instability and although there was no significant difference as regards stability in flexion and torsion between all groups, the stretch attained from the posterior in axial loading and in flexion were greater than that was attained in the group to which anterior fixation was applied, and as a result of these findings, they concluded posterior fixation techniques yielded better results. It is the commonly held opinion that in the cases of total discoligamentous injuries, anterior fixation

may be ineffective because it is far from the instantaneous axis of rotation during flexion. Smith in his study, showed that anterior flexion provided stability in flexion in his subjects, but that this amount of stability was less than that provided in the control group (14). Similar results were supported by Cosper and Goel (8). For all these reasons, some researchers put forward the idea that combined (anterior-posterior fixation) intervention may provide stability in total discoligamentous injuries. Coe and his colleagues (3, 17) displayed that anterior and posterior combined fixation has been the most efficient way of stabilization in the treatment of discoligamentous injuries (11). However, there are no defenders of this view because of the difficulties in this kind of approach. As was shown experimentally by White and confirmed by Stauffer, if the lesion was in the posterior, fusion should be done posteriorly. If fusion was done at the intact side, ligamentous injury which might cause vertebral collapse was due to the surgery in the intact side (5). Weidner, reviewed the indications and contraindications of cervi-

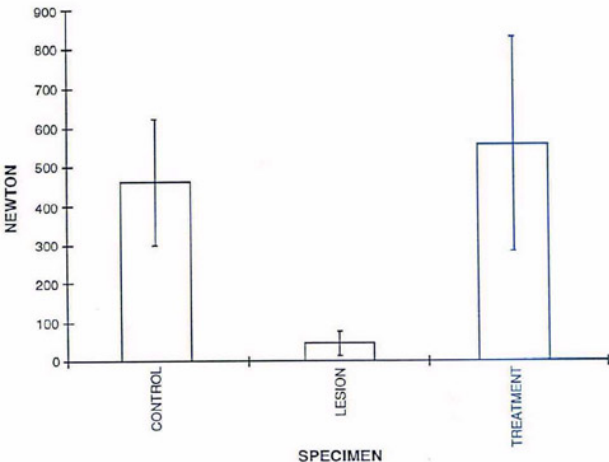


Figure 2. Comparison of groups under extension forces

cal spinal stabilization, and reported that the stabilization should be performed posteriorly if the instability is localized posteriorly (18). Glasser et al (7) reported that interspinous wiring and bone fusion provided sufficient stabilization in patients of traumatic posterior ligamentous injuries and stressed the efficacy of the interspinous wiring method as well as its technical ease, although they were not utilized in fractured spinous processes or laminae. Jeanneret and Magerl (9) demonstrated that posterior fixation was more rigid than anterior plating in all flexion tests. Optimal therapeutic approaches of cervical trauma with ligamentous injury necessitated surgical stabilization. Posterior fixation and fusion maintained the best stabilization for cervical trauma with subaxial ligamentous injury by forming the tension band between the affected verte-

brae. Geisler (6) and colleagues concluded that the use of wires created the primary stabilization required, and allowed for an earlier mobilization of the patient, while awaiting the proper fusion of the bony material (10). In summary, in reviewing all flexion type cervical traumas, that is to say, discoligamentous injuries, potential risks of spinal instability and surgical treatment resulted in two questions, the first was related to the type of surgical intervention and the second was related to the method of internal stabilization utilized. In order to preserve the stability in the intact anterior portion of the vertebral column, posterior approach became the preferred surgical intervention to establish stability. In this context while posterior fixation was an easy answer in the case of posterior discoligamentous injuries, it was not so easy to utilize this approach for

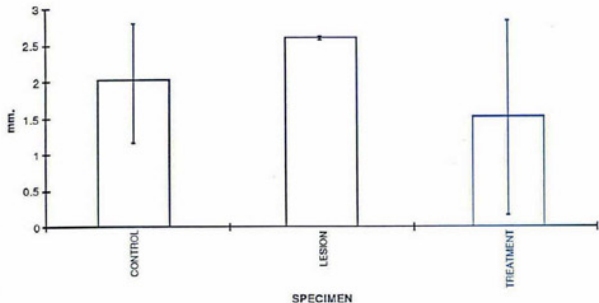


Figure 3. Comparison of groups under axion forces

complete discoligamentous injuries. Considering the difficulties of combined surgical interventions, posterior fixation was found to be the most suitable technique for sufficient resistance against flexion loading in all studies and it was also found to be more efficient than anterior stabilization. Selection of Bohlman's triple secondary to the ease of application and acquisition as well as the absence of economical restriction answers the second question.

At the beginning of this study, calculations were carried out to determine the amount of force which caused a unit displacement under flexion, extension and axial loading, in the subjects of the control group. Then, the resistance of the intact subjects demonstrated against the various directional forces applied, composed the numerical data of stability. By comparing the resistance shown under force application in the subjects of lesion with the one shown by the control group, it was detected that the lesion induced in this group caused instability which was statistically significant. The treatment group was composed of subjects which were first made unstable using an iatrogenic lesion, which was then repaired with posterior fixation. The measure of adequate stability provided by posterior fixation was shown to be equal to and surpassed the

values of those in the control group. In fact, the force which produced 1 cm displacement in flexion loading in the control group was 607.67 N while it was 1883.5 N in the group where posterior fixation was utilized. The difference was statistically significant ($p = 0.03$). The resistance of the subjects whose stability was provided using posterior fixation, was stronger than the ones demonstrated using intact cervical specimens. Measurements for the control group in extension was 470.3 N, and 562 N in the group in which posterior fixation was utilized. There was no statistically significant difference. This demonstrated that posterior fixation, utilized in the cure of total discoligamentous injuries, provided a stronger stability in flexion. While it was detected that there was 2.01 mm displacement in the control group for the axial loading of 300 N, this dropped to 1.51 mm in the treatment group. The statistically insignificant difference ($p = 0.511$) showed the adequacy of stabilization. The displacement was found to be 5.71 mm in the control group, and 9.77 mm in the posterior fixation group under a lateral flexion loading of 300 N. The statistically insignificant difference ($p = 0.222$) demonstrated that a resistance approximately equivalent to intact vertebrae was provided.

CONCLUSION

The data of this study concurred with the data found in the literature. When all values were considered, the results of subjects to which fixation was applied produced better results than the results of the control group in flexion. Thus a more resistant stability was attained than that which the intact vertebrae had attained in flexion loading. Equivalent values to the control group were attained in the other loading. The study which determined that posterior fixation is a way of internal stabilization and provides necessary stabilization in adequate levels, in current clinical practice, also confirmed the reliability of the utilized technique. The effectiveness of the stabilization, the low surgical risks and the superiority of its advantages, present posterior fixation as a convenient way of treatment in total discoligamentous injuries of the cervical region.

REFERENCES

- Adams MA, Hutton WC; The effect of fatigue on the lumbar intervertebral disc. *J. Bone Joint Surg.* 65B: 199-203, 1983.
- Allen BL, Ferguson RL, Lehmann TR, O'Brien RP; A mechanistic classification of closed, indirect fractures and dislocations of lower cervical spine. *Spine* 7: 1-27, 1982.
- Coe JD, Warden KE, Sutterlin CE, McAfee PC; Biomechanical evaluation of cervical spinal stabilization methods in a human cadaver model. *Spine* 14: 1122-1131, 1989.
- Errico TJ, Waugh T, Bauer D; Spinal trauma. Philadelphia: JB Lippincot Co, 1991: 71-122.47
- Fielding JW; Cervical spine surgery. *Clinical Orthopaedic and Related Sciences* 200: 284-290, 1985.
- Geisler F.H., Mirvis S.E., Zrebeet H, Joslyn J; Titanium wire internal fixation for stabilization of injury of the cervical spine. *Neurosurg.* 25: 356-362, 1989.
- Glasser R.S., Fessler R.G; Posterior cervical spine fixation. *Contemporary Neurosurgery* 15: 1-8, 1993.
- Goel VK, Clark CR, Harris KG, Schulte KR; Kinematics of the cervical spine: Effects of multiple total laminectomy and facet wiring. *J. Orthop Res.* 6: 611-619, 1988.
- Jeanneret B, Magerl F, Ward E.H., Ward J. Ch; Posterior stabilization of the cervical spine with hook plates. *Spine* 16S: 56-63, 1991.
- Kaufman III, Jones E; The principles of bony fusion. *Neurosurgery* 24: 264-270, 1989.
- Lemos VBR, Wagner FC; Stabilization of subaxial cervical spinal injuries. *Surge Neural* 39: 511-18, 1993.
- Panjabi MM, Krag M, Summers DJ; Biomechanical time tolerance of fresh cadaveric human spine specimens. *J. Orthop Res.* 3: 292-300, 1985.
- Shono Y, McAfee PC, Cunningham BW; The pathomechanics of compression injuries in the cervical spine: nondestructive and destructive investigative methods *Spine* 18: 2009-2019, 1993.
- Smith SA, Lindsey RW, Doherty BJ, Alexander JW, Dickson JI; Cervical spine locking plate: in vitro biomechanical testing *Eur Spine J* 1: 222-225, 1993.
- Sutterlin CE, McAfee PC, Warden KE, Rey MR, Farey ID; A biomechanical evaluation of cervical spinal stabilization methods in a bovine model. Static and cyclical loading. *Spine* 13: 795-802, 1988.
- Ulrich C, Woerdsorfer O, Claes L, Magerl F; Comparative study of stability of anterior and posterior cervical spine fixation procedures *Arch Orthop Trauma Surg.* 106: 226-231, 1987.
- Virgin W; Experimental investigations into physical properties of intervertebral disc. *J Bone Joint Surg* 33B: 607-611, 1951.
- Weinder A, Chioe St, Schumacher HW; Indications and complications of cervical spine stabilization in Bushe KA, Brock M, Klinger M (eds) *Advances in Neurosurgery*. Vol 18 Berlin Heidelberg: Springer-Verlag, 1990: 19-23.